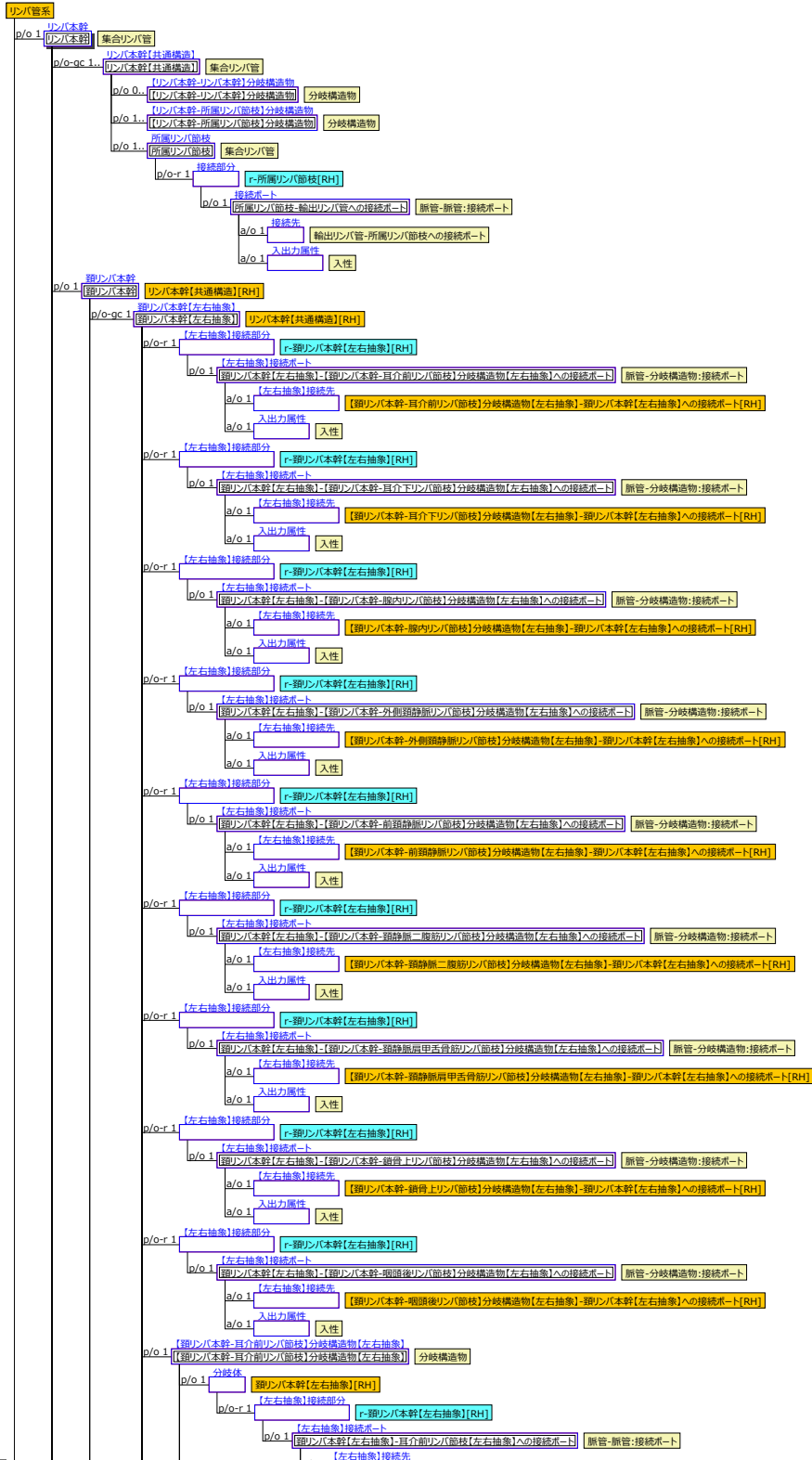

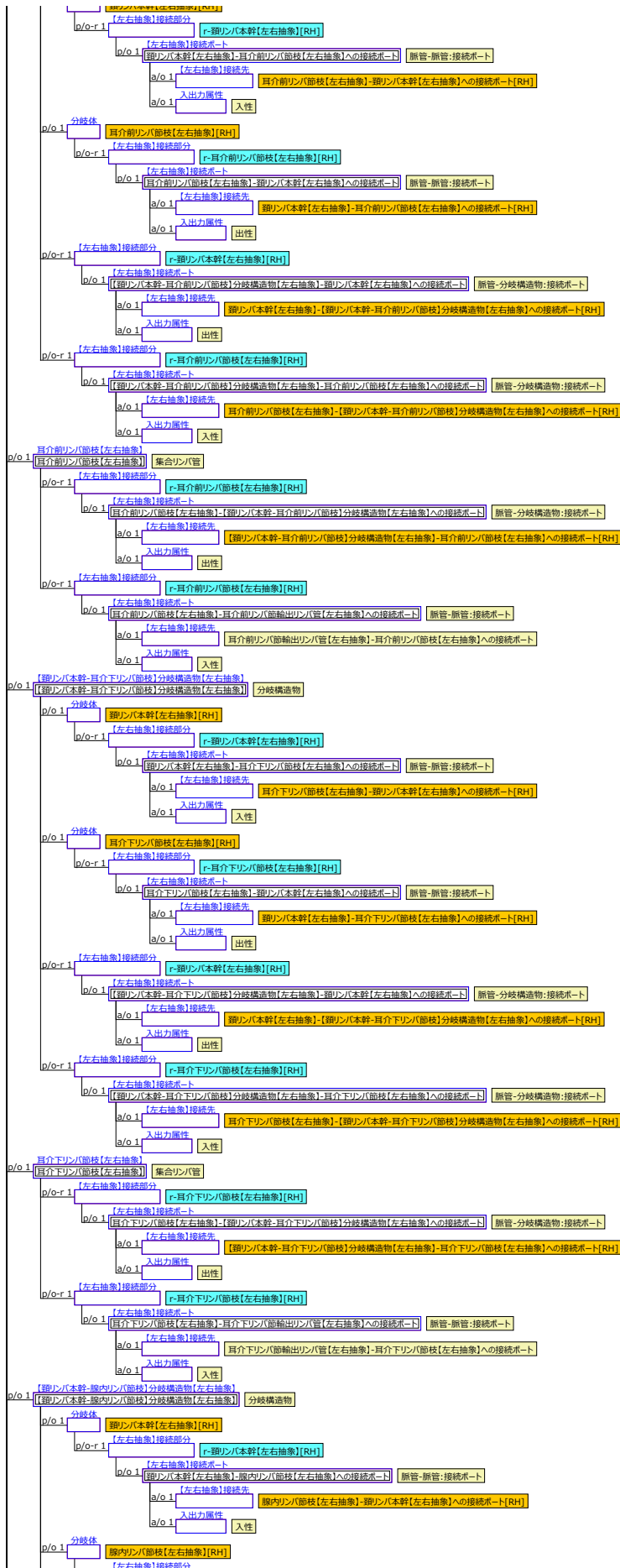
[Class Name] リンパ管系

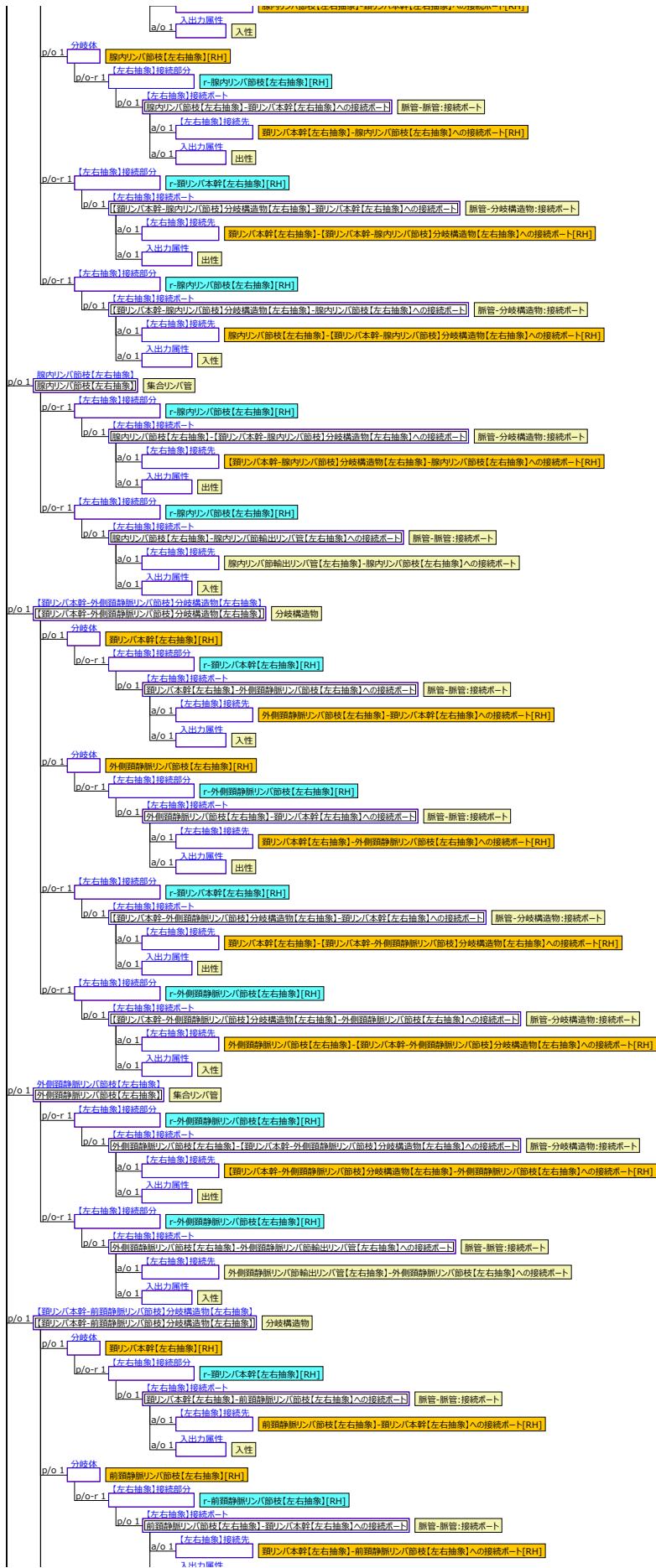
[Super Classes] リンパ管系

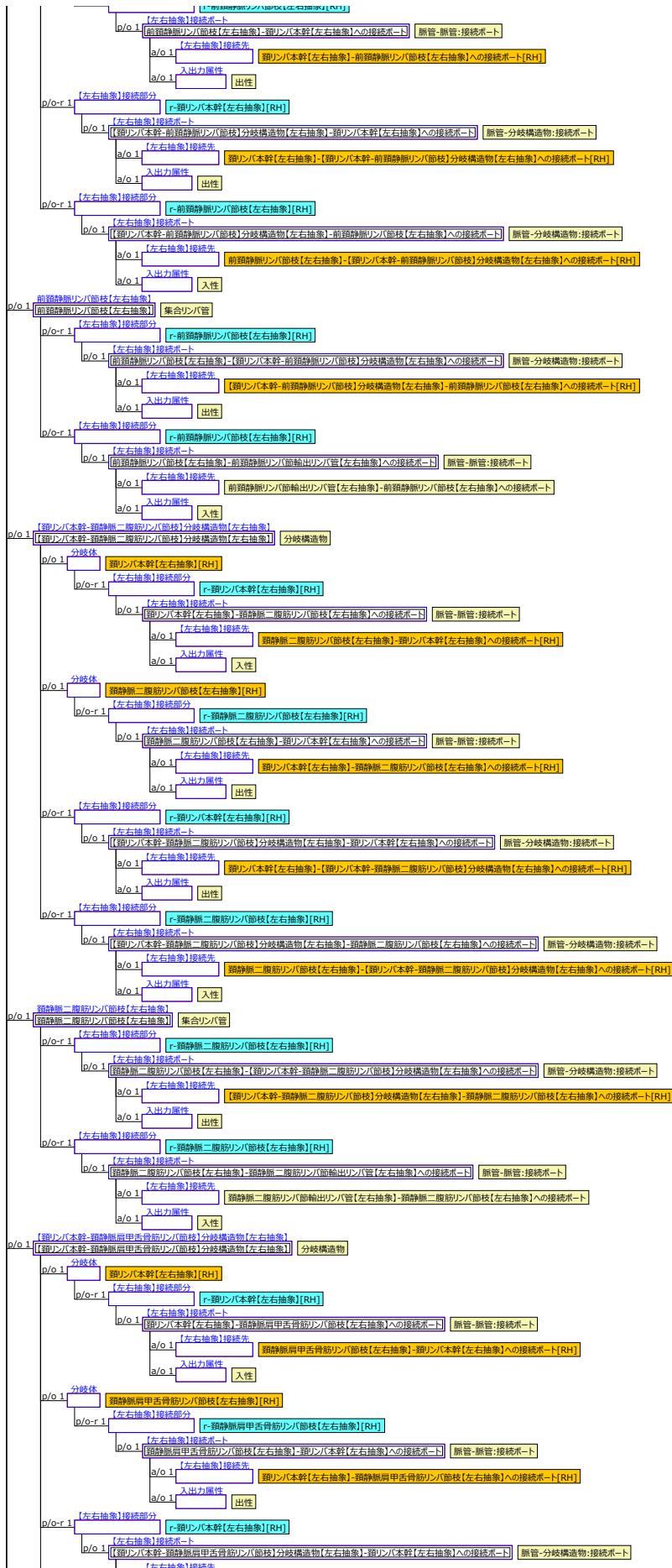
[Sub Classes]

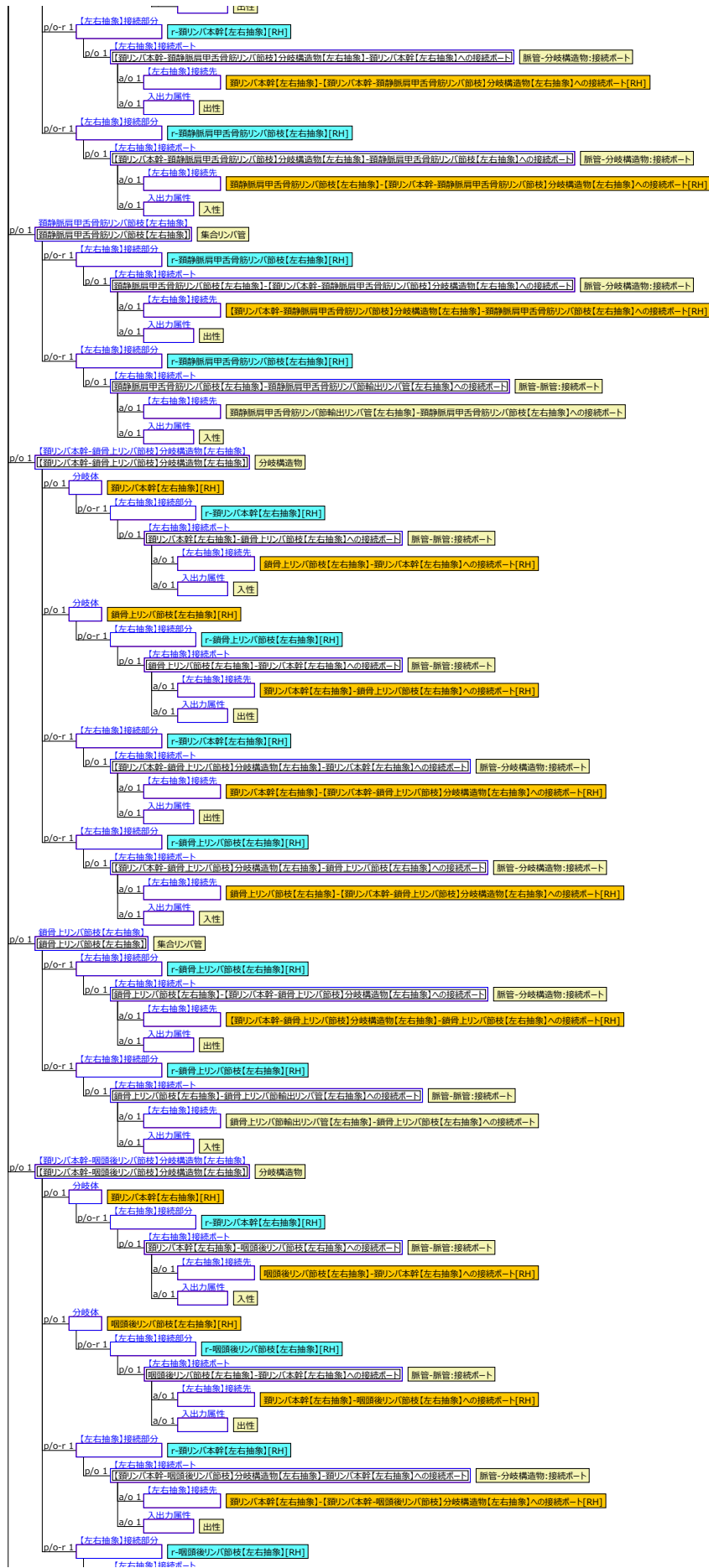
[Graph (32%)]

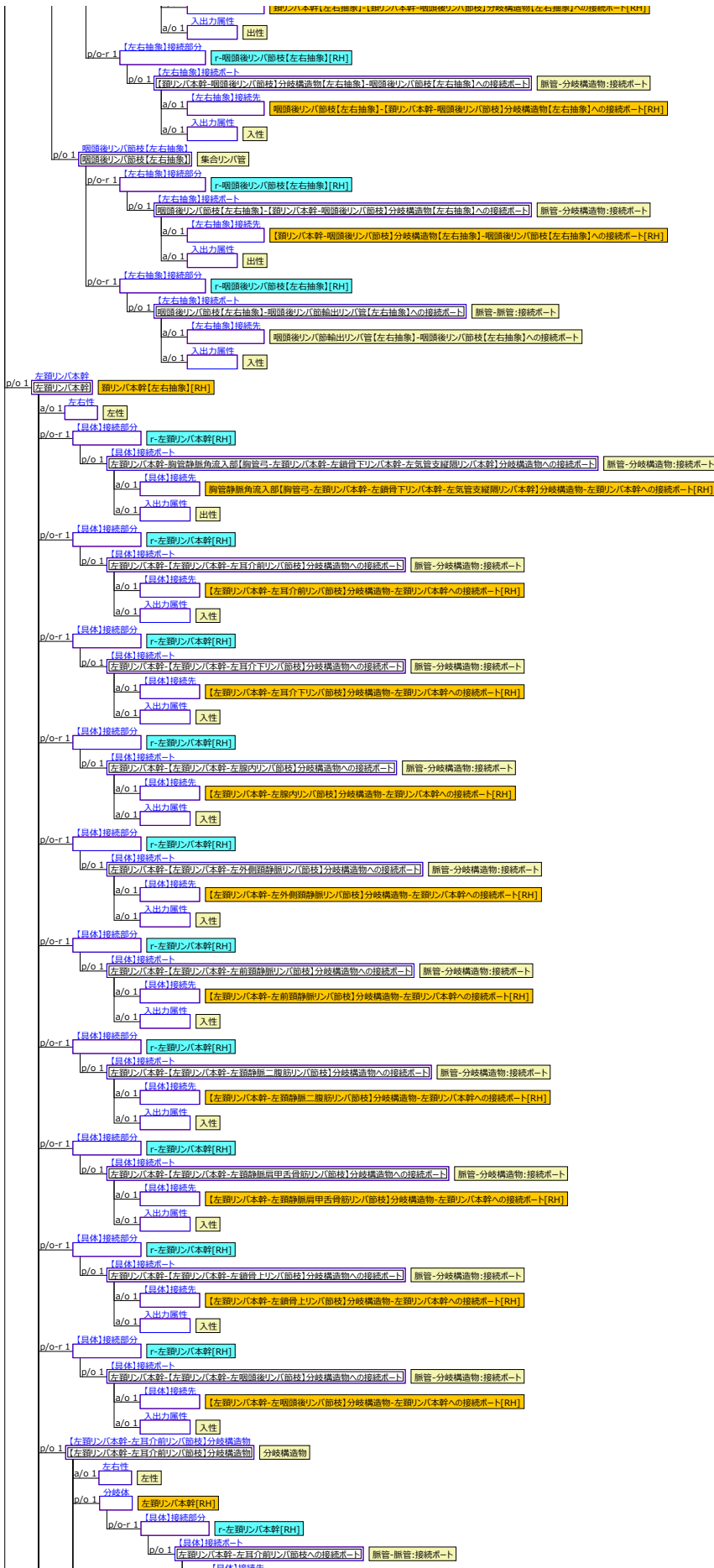


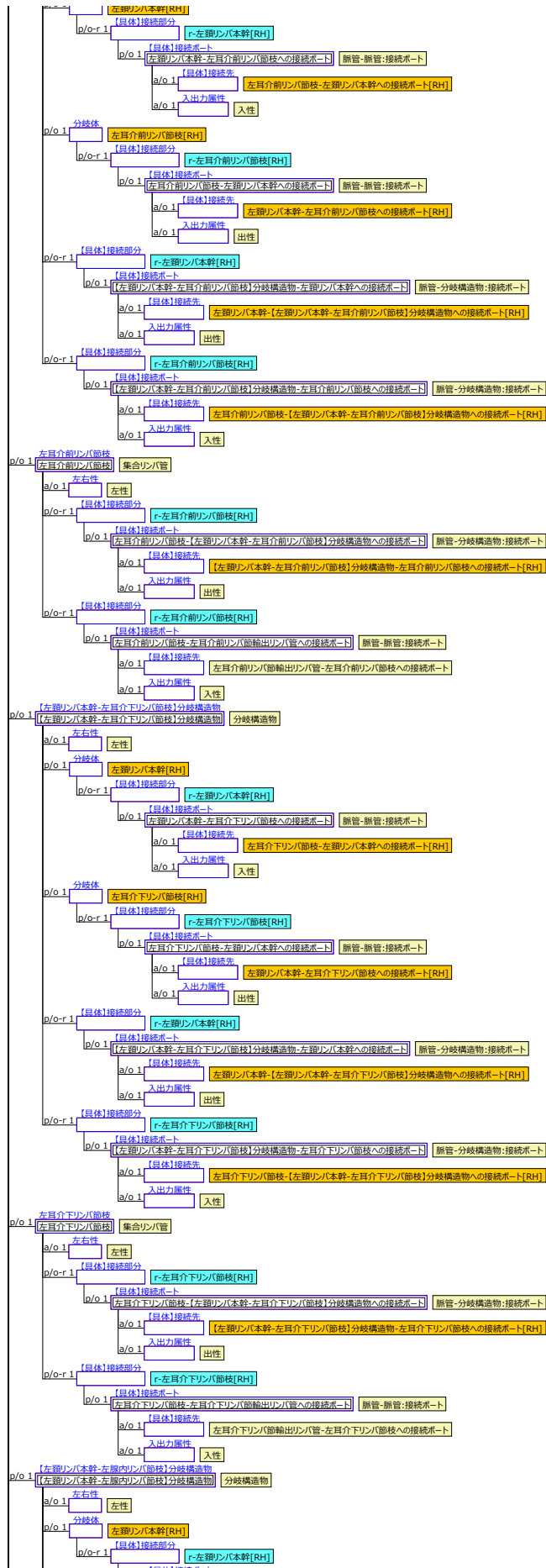








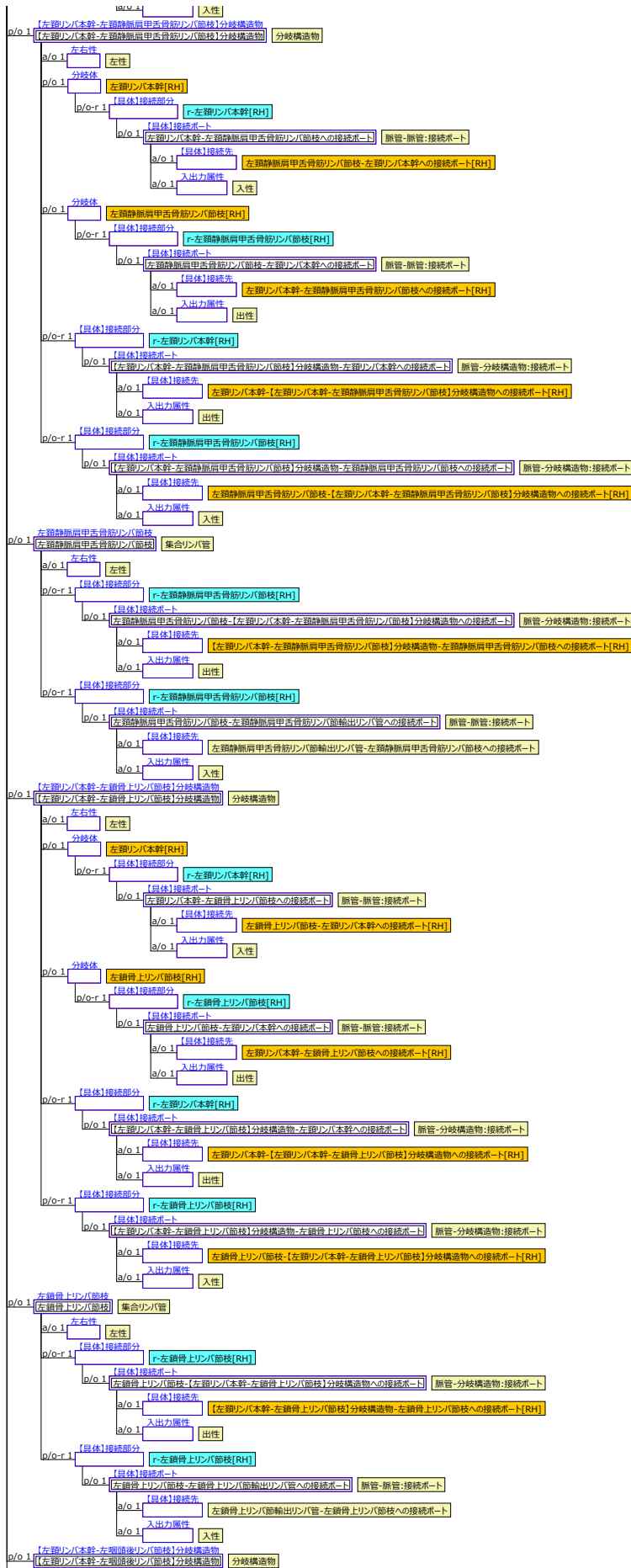


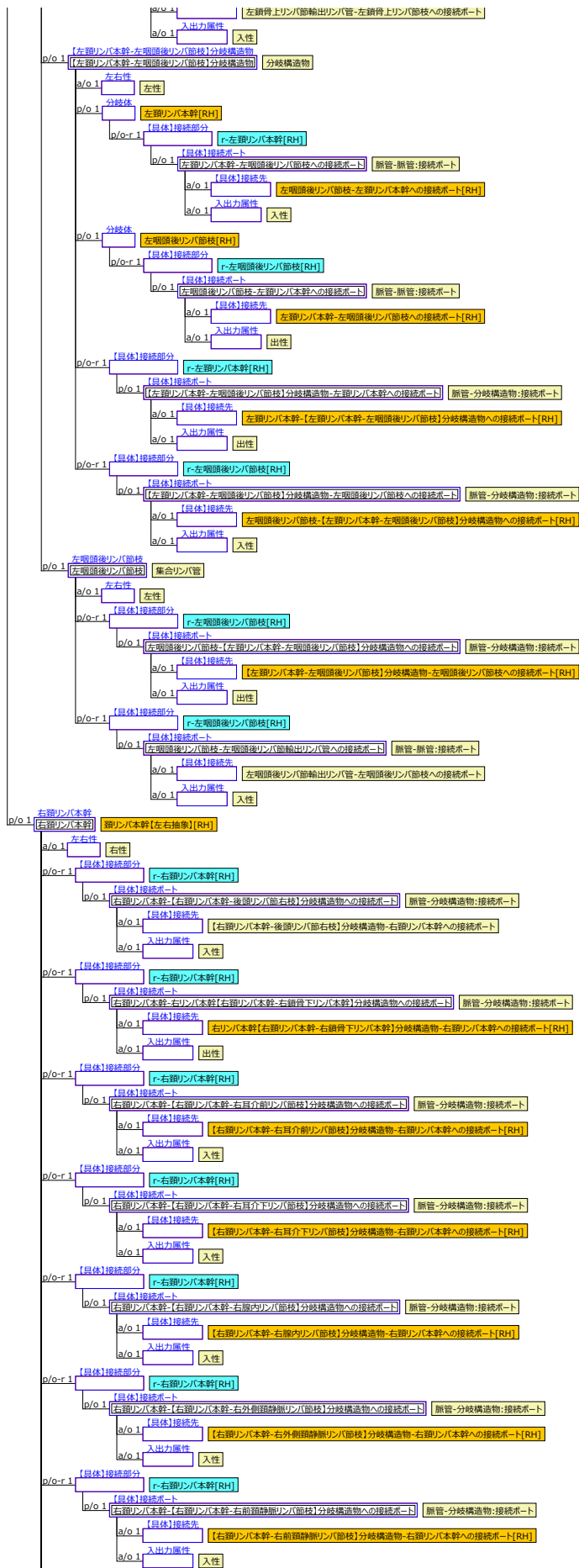




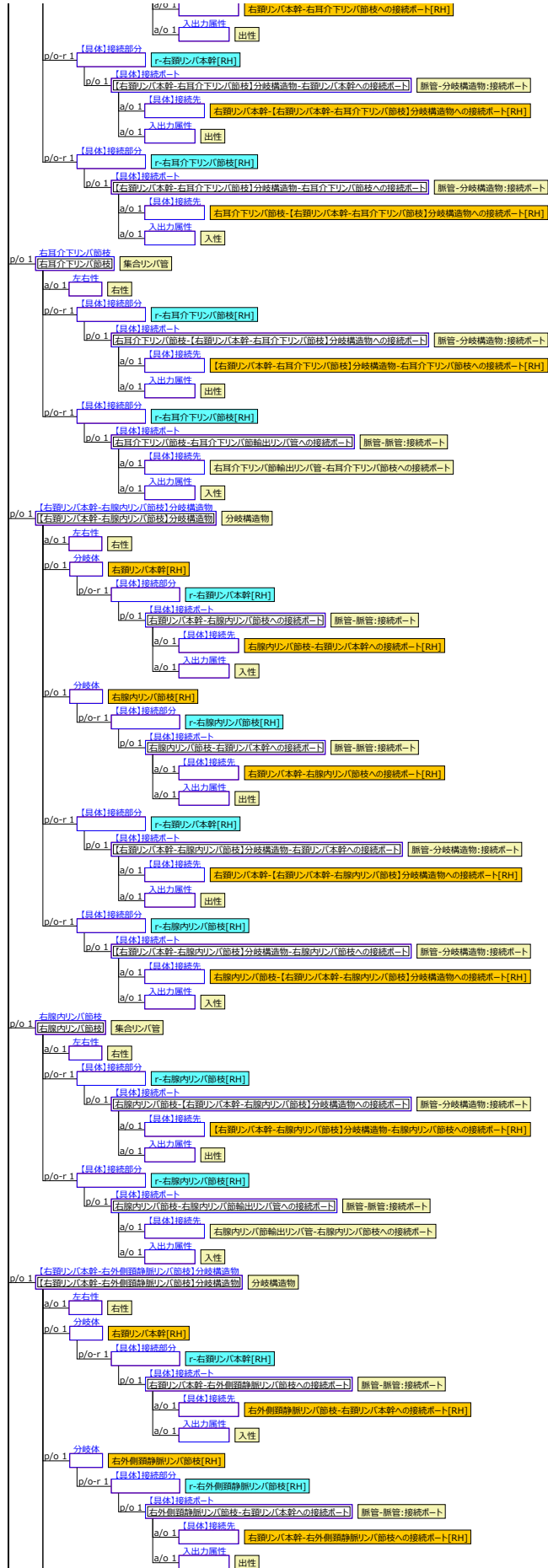


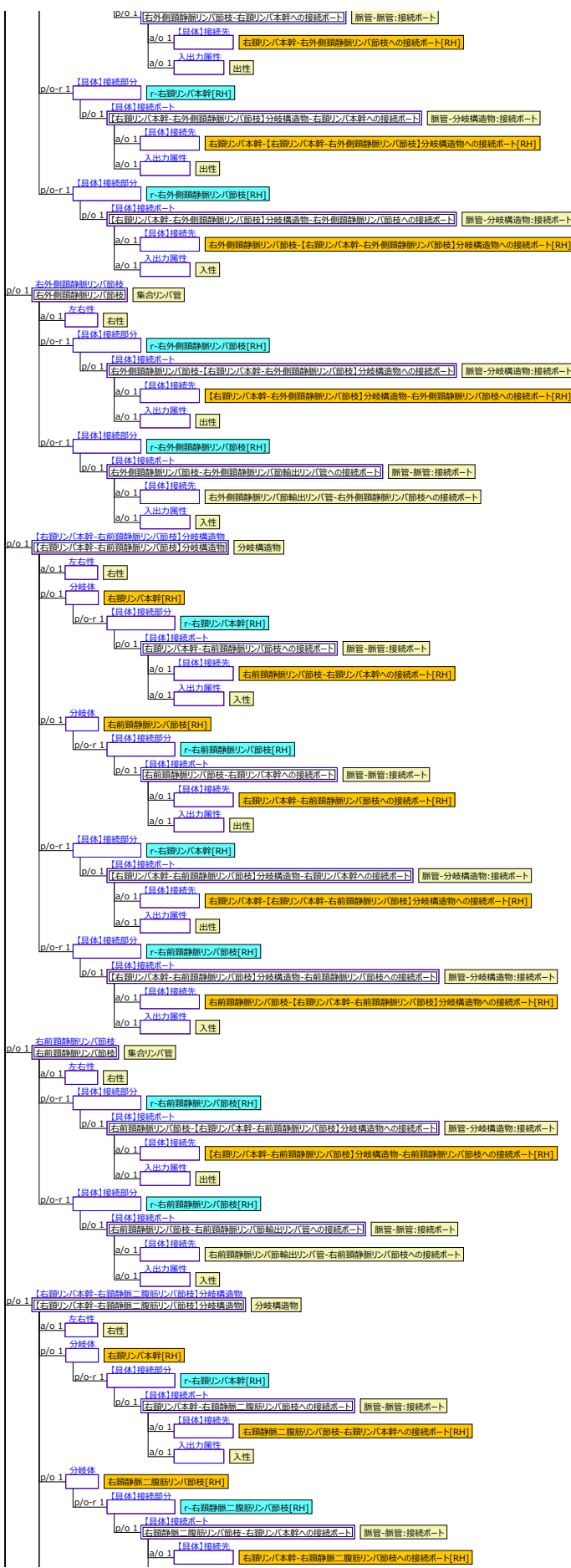








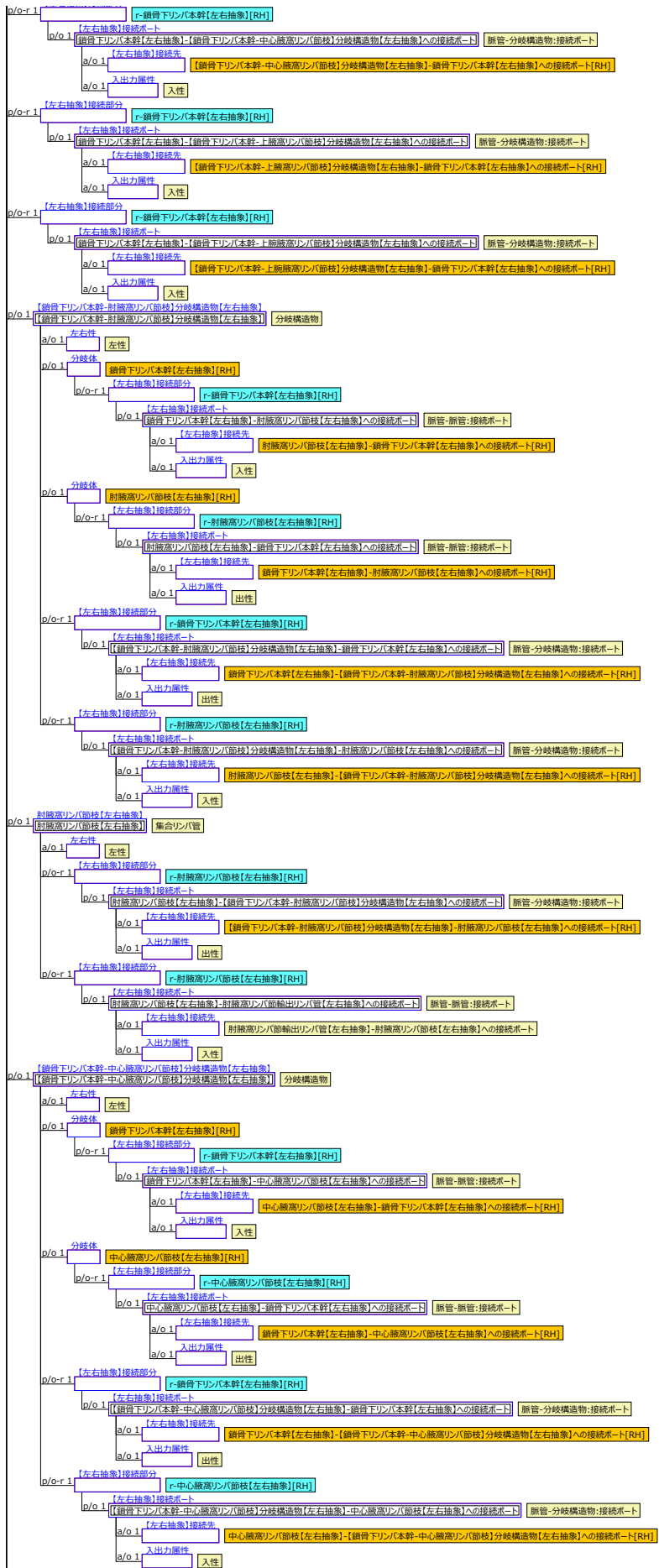


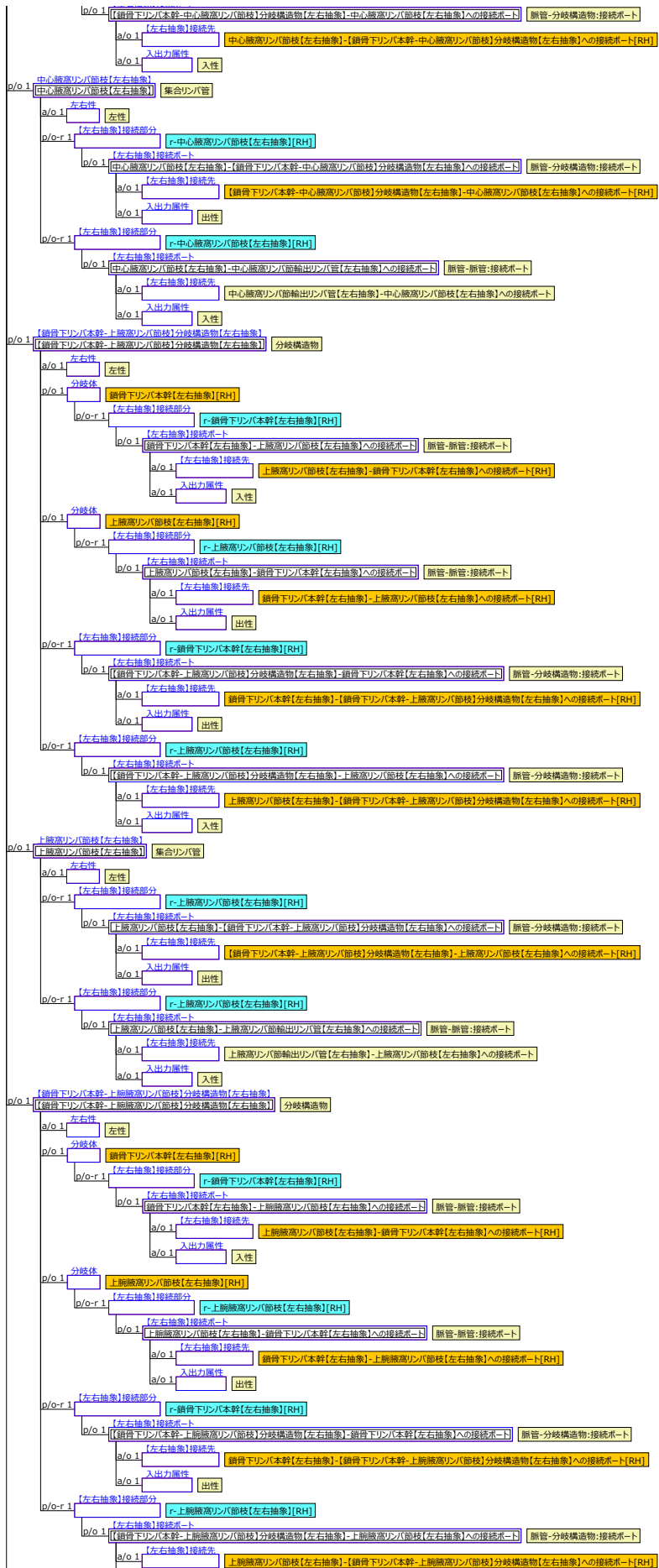




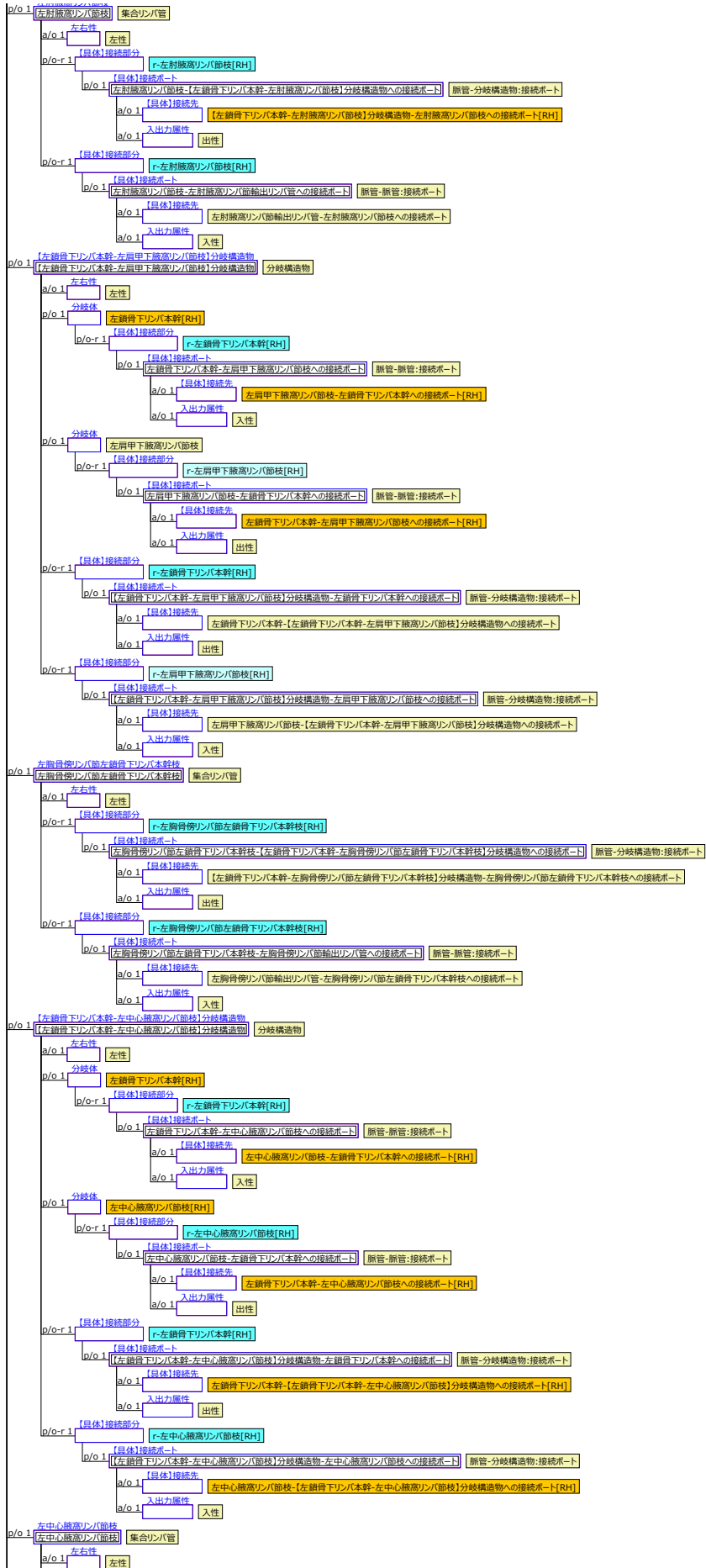


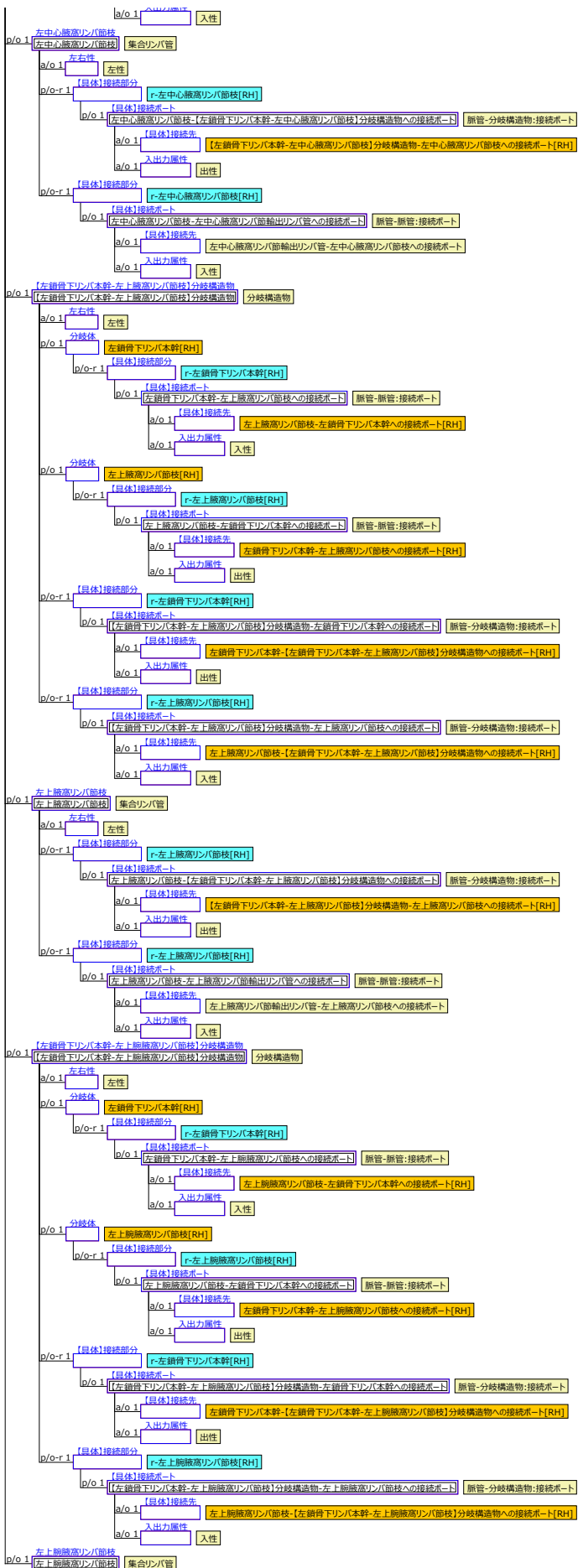


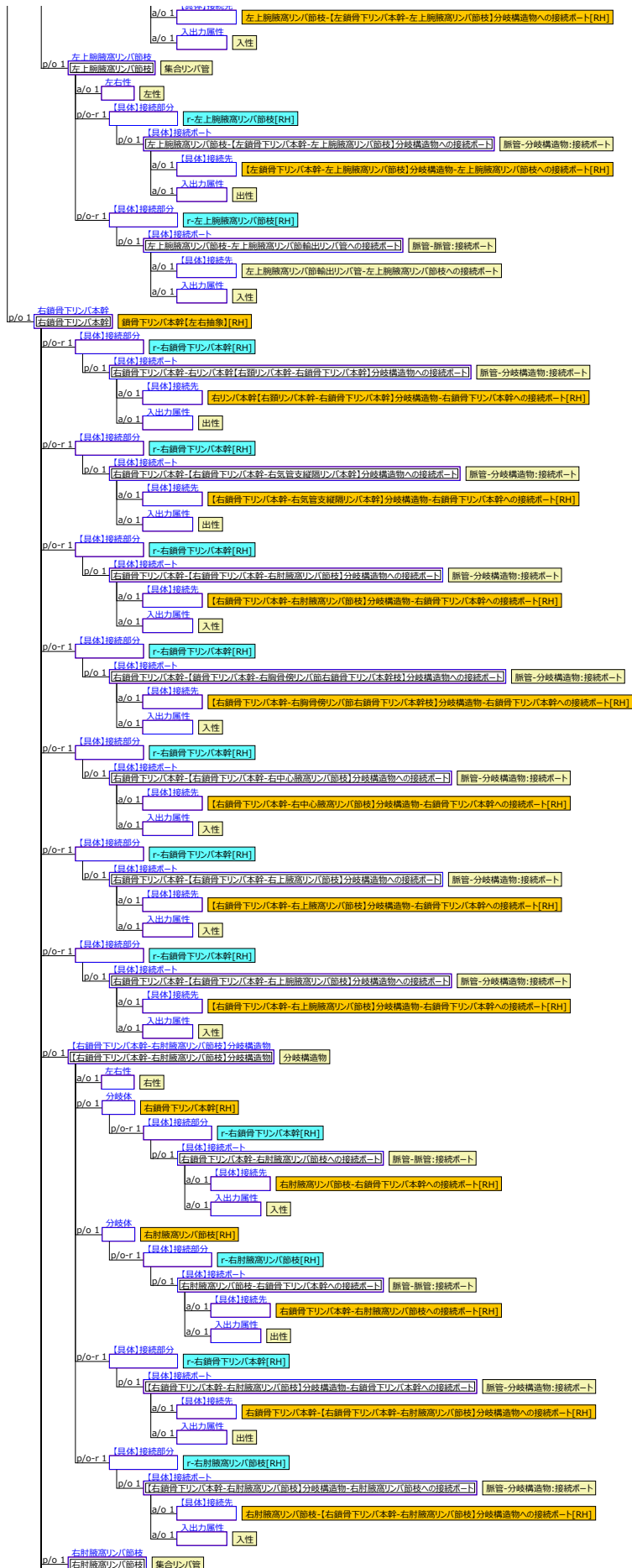


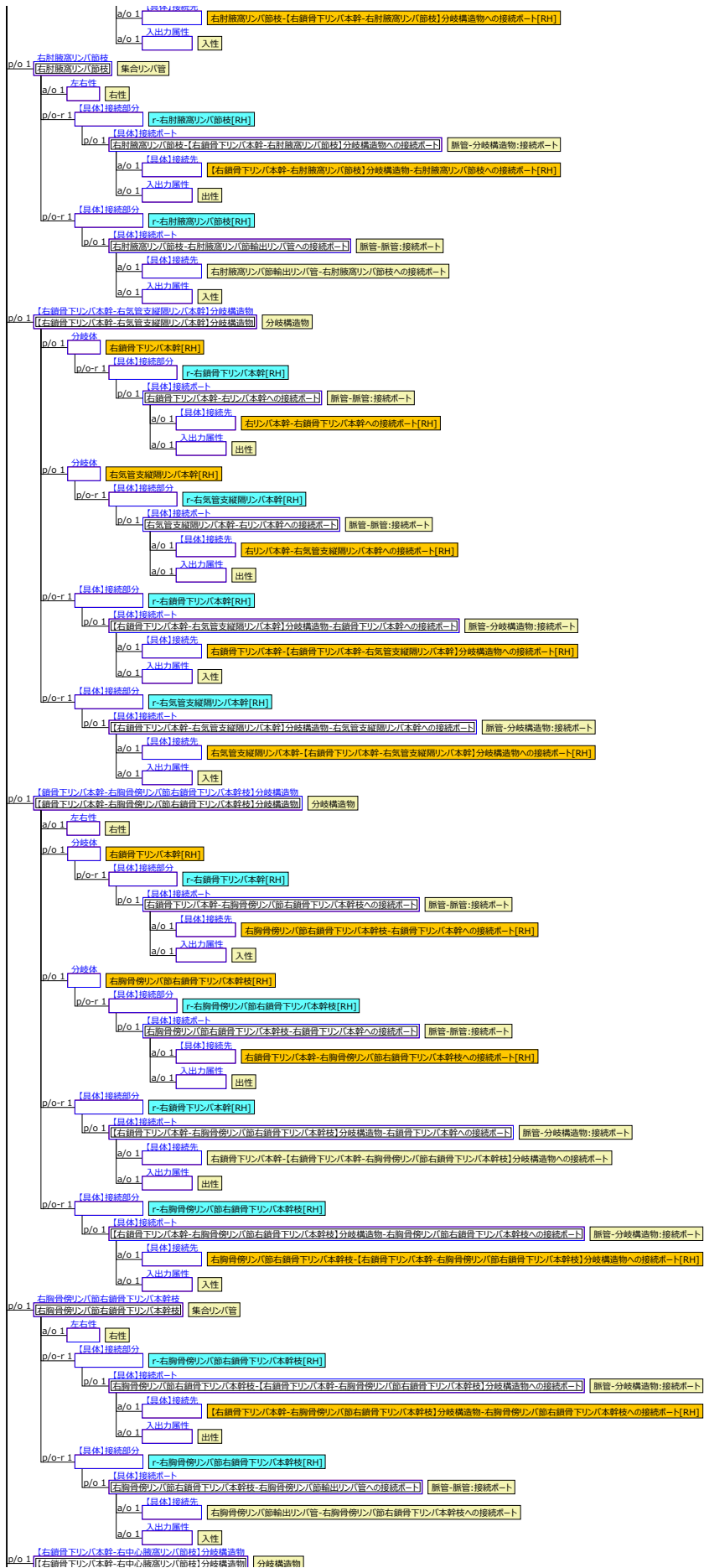


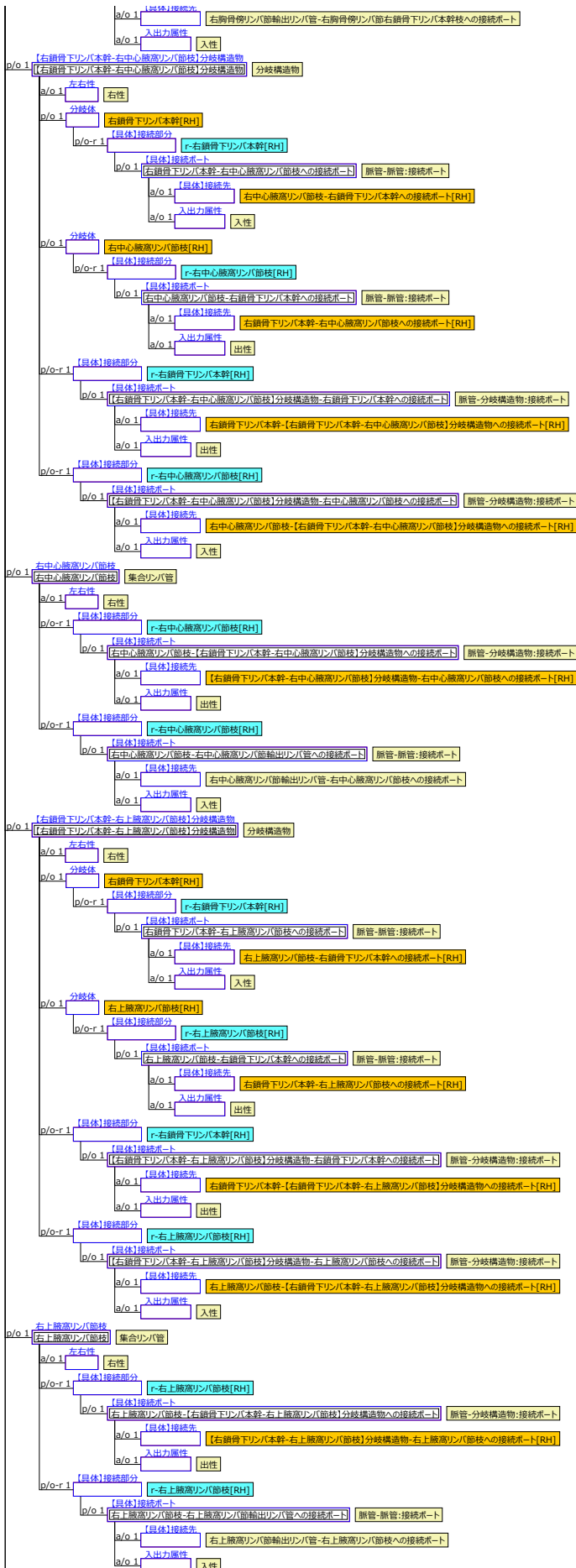




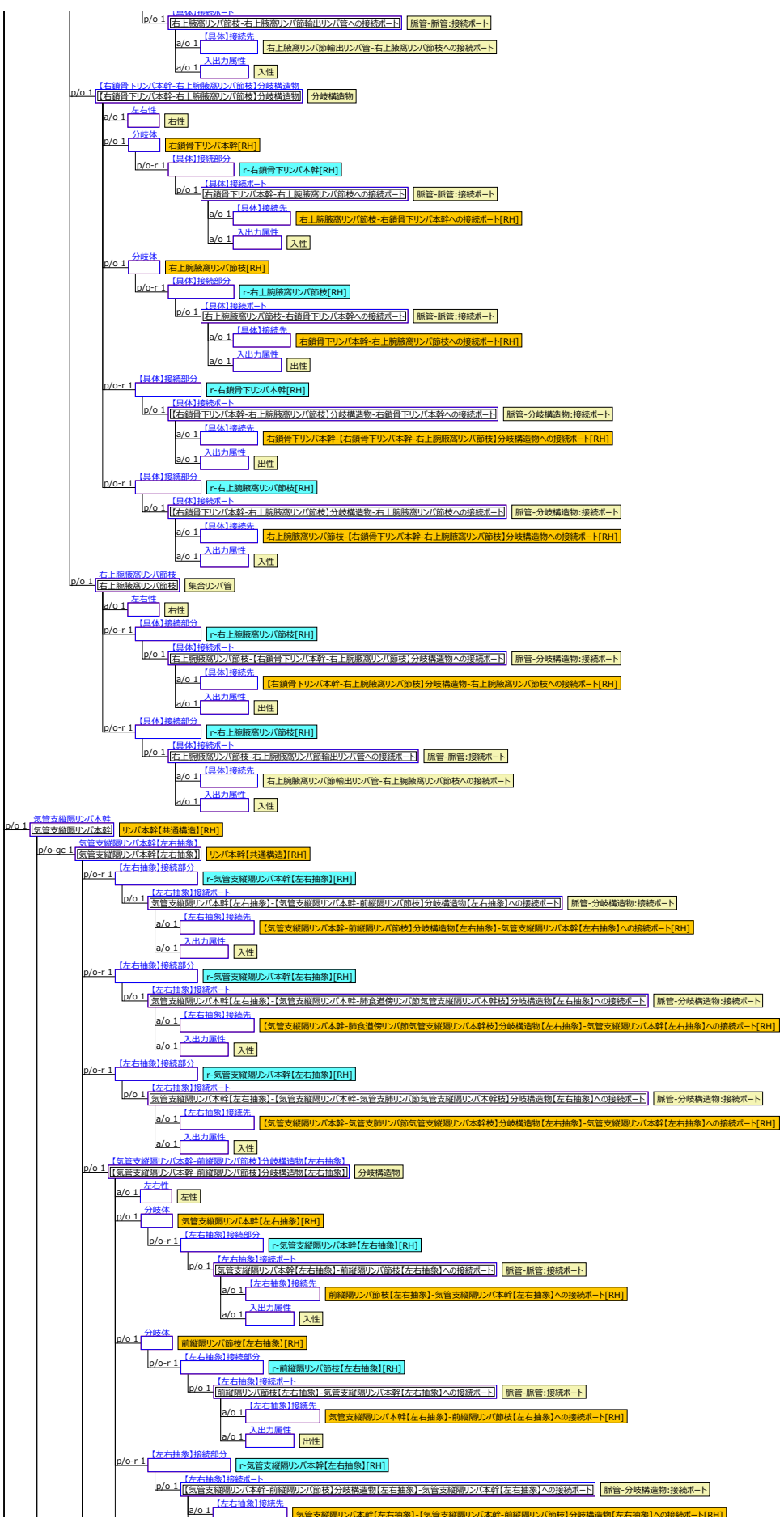


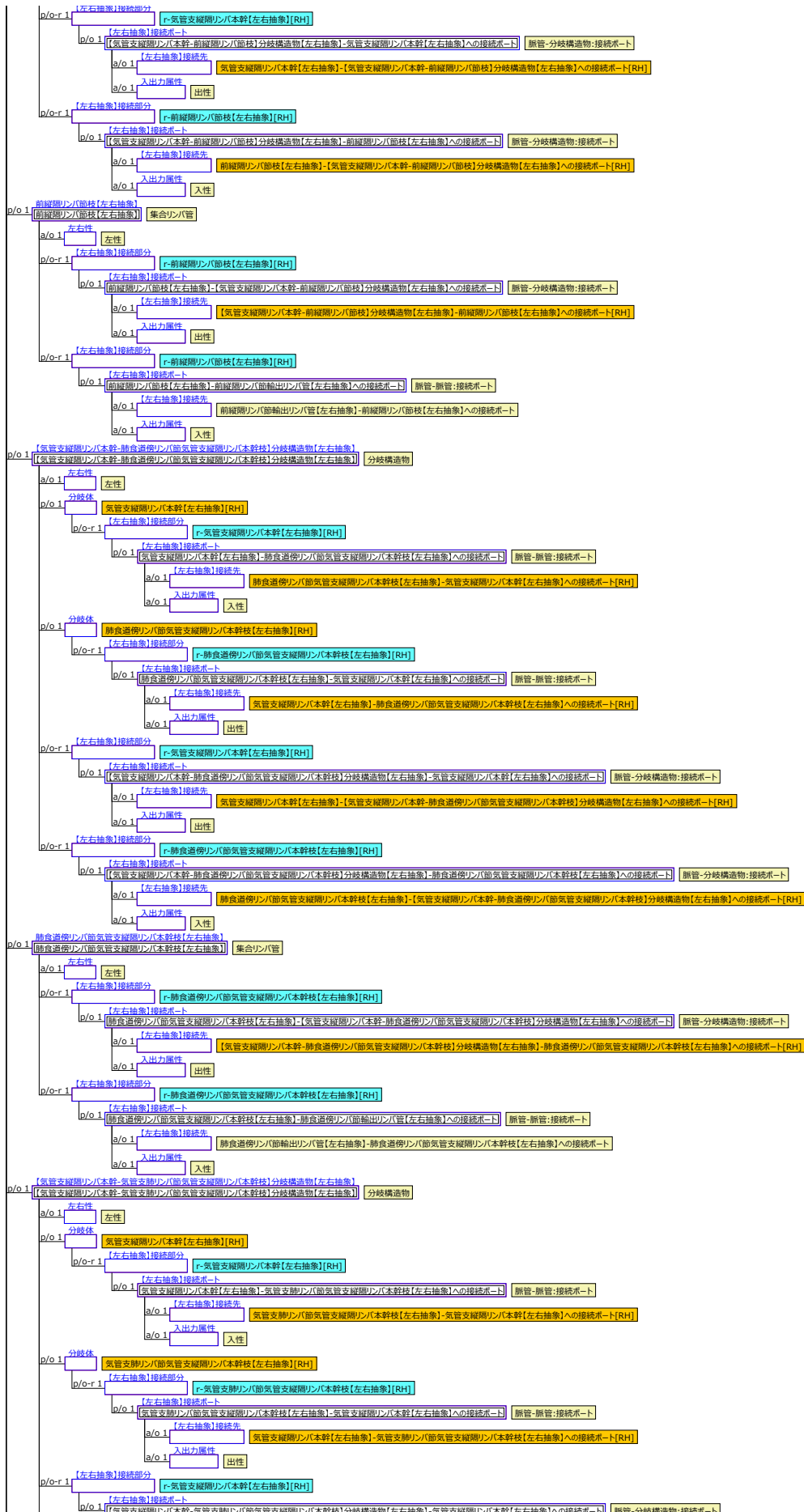


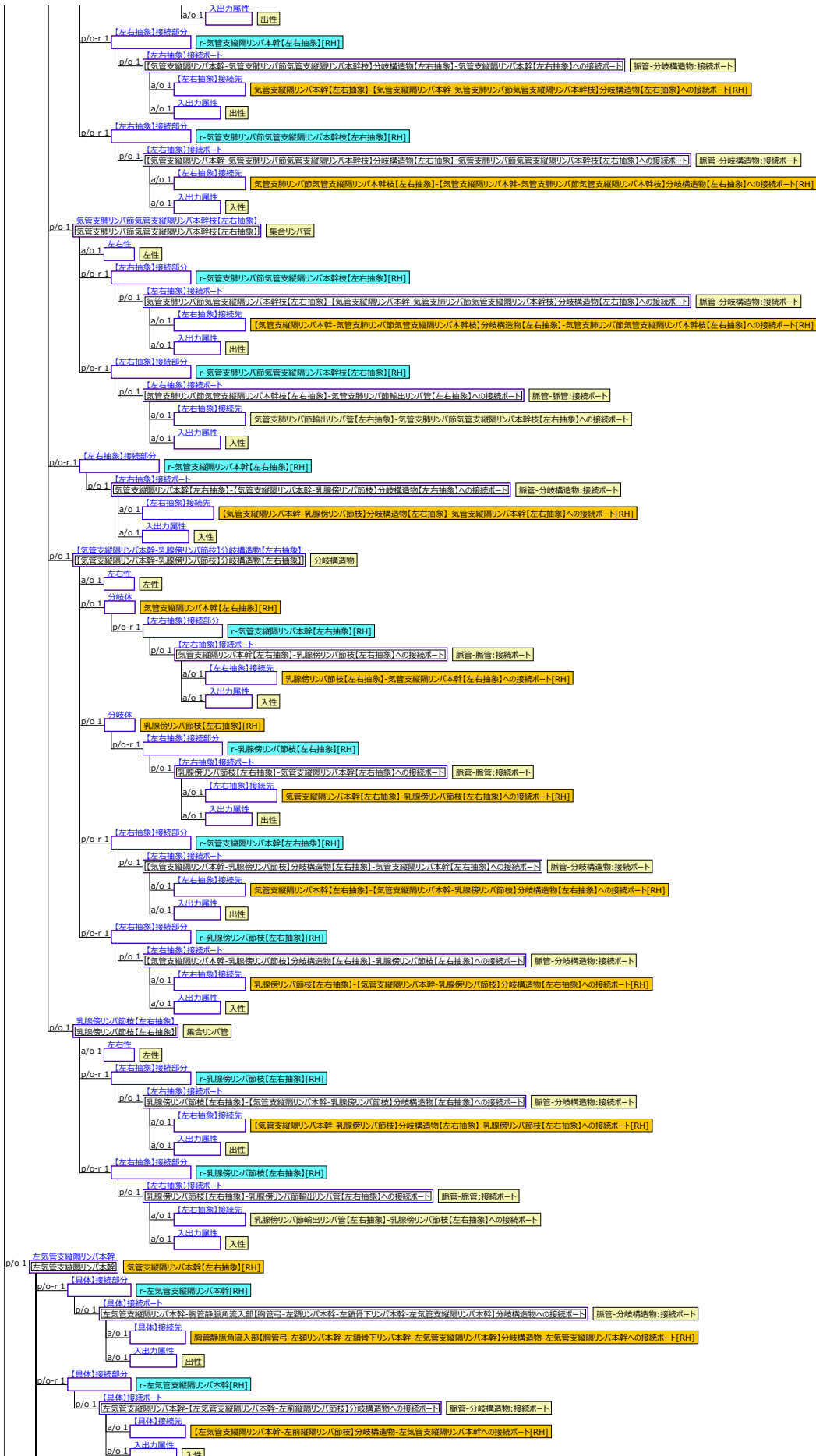


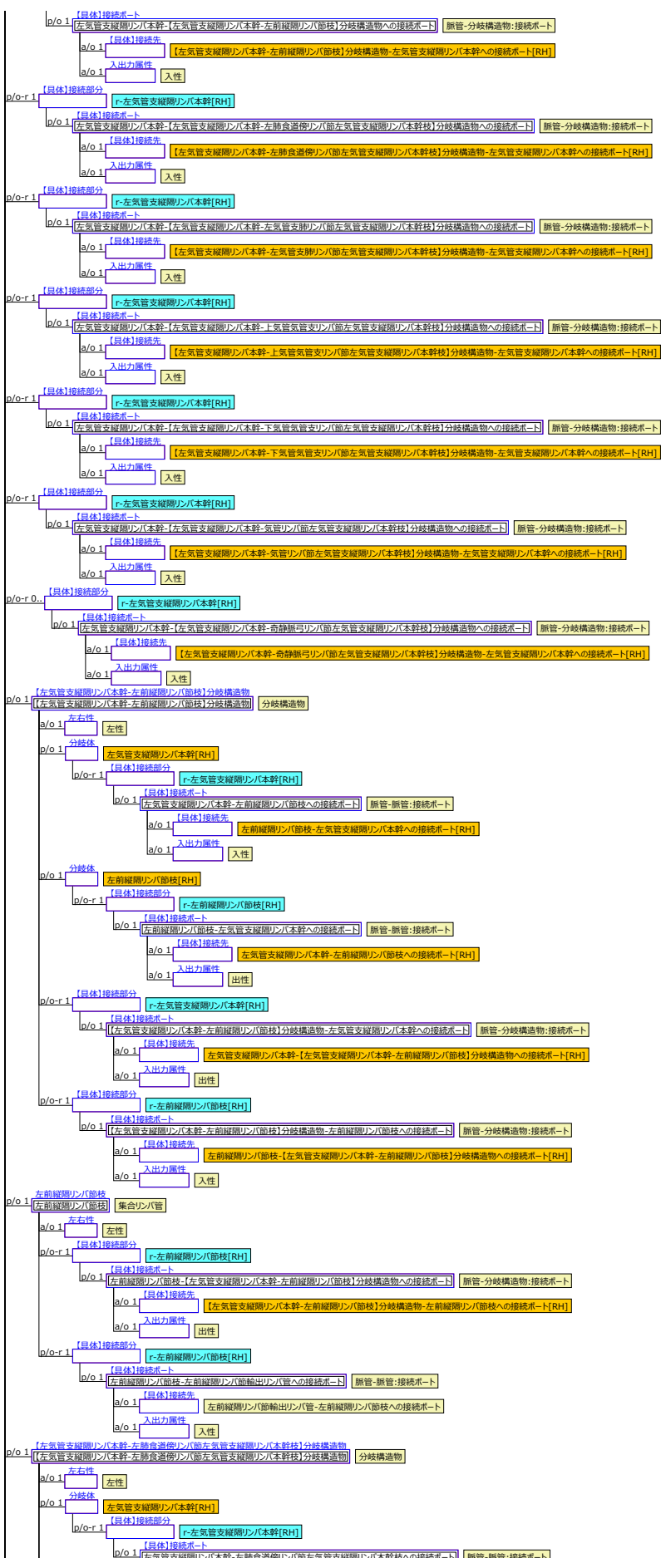


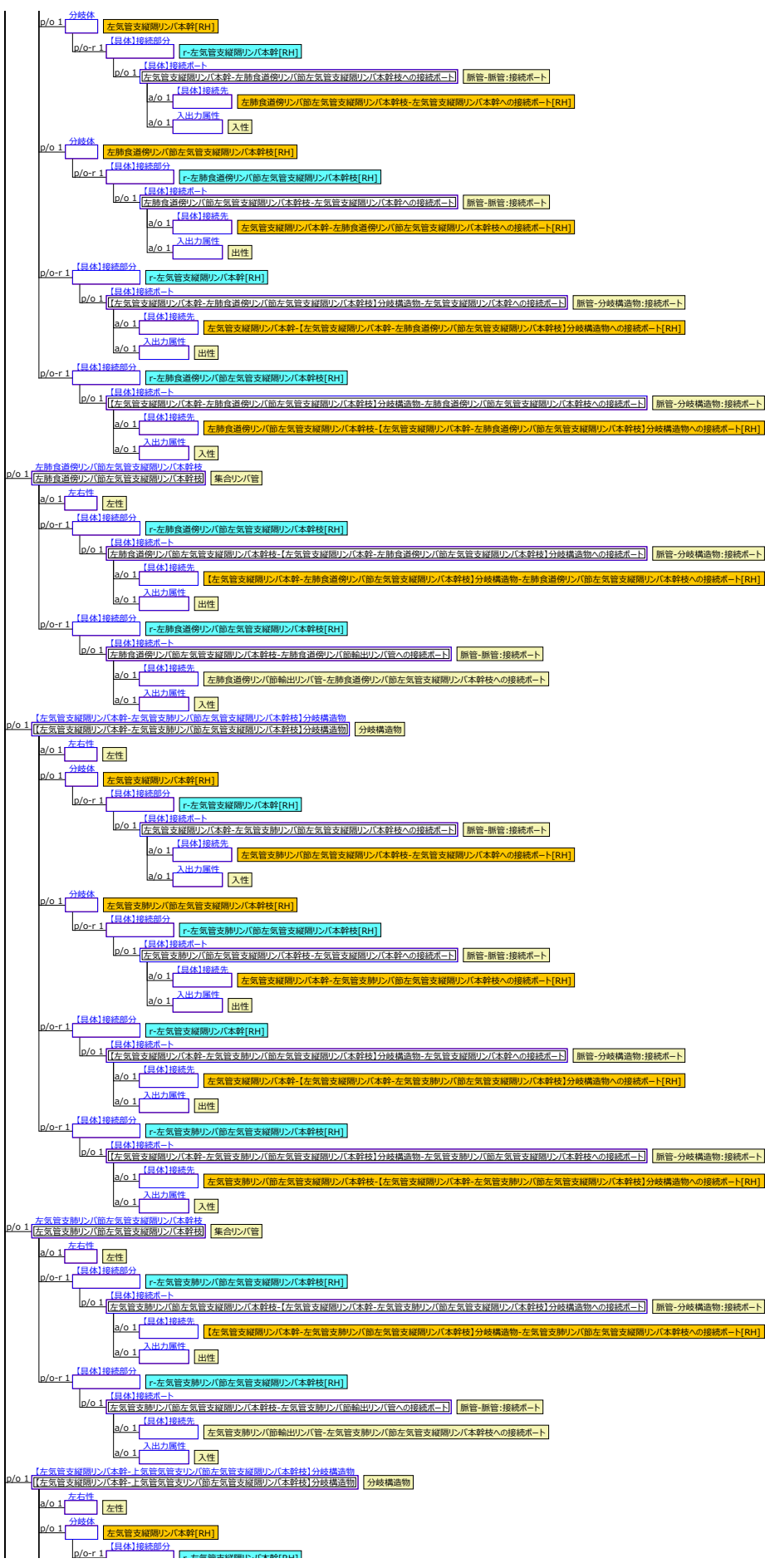


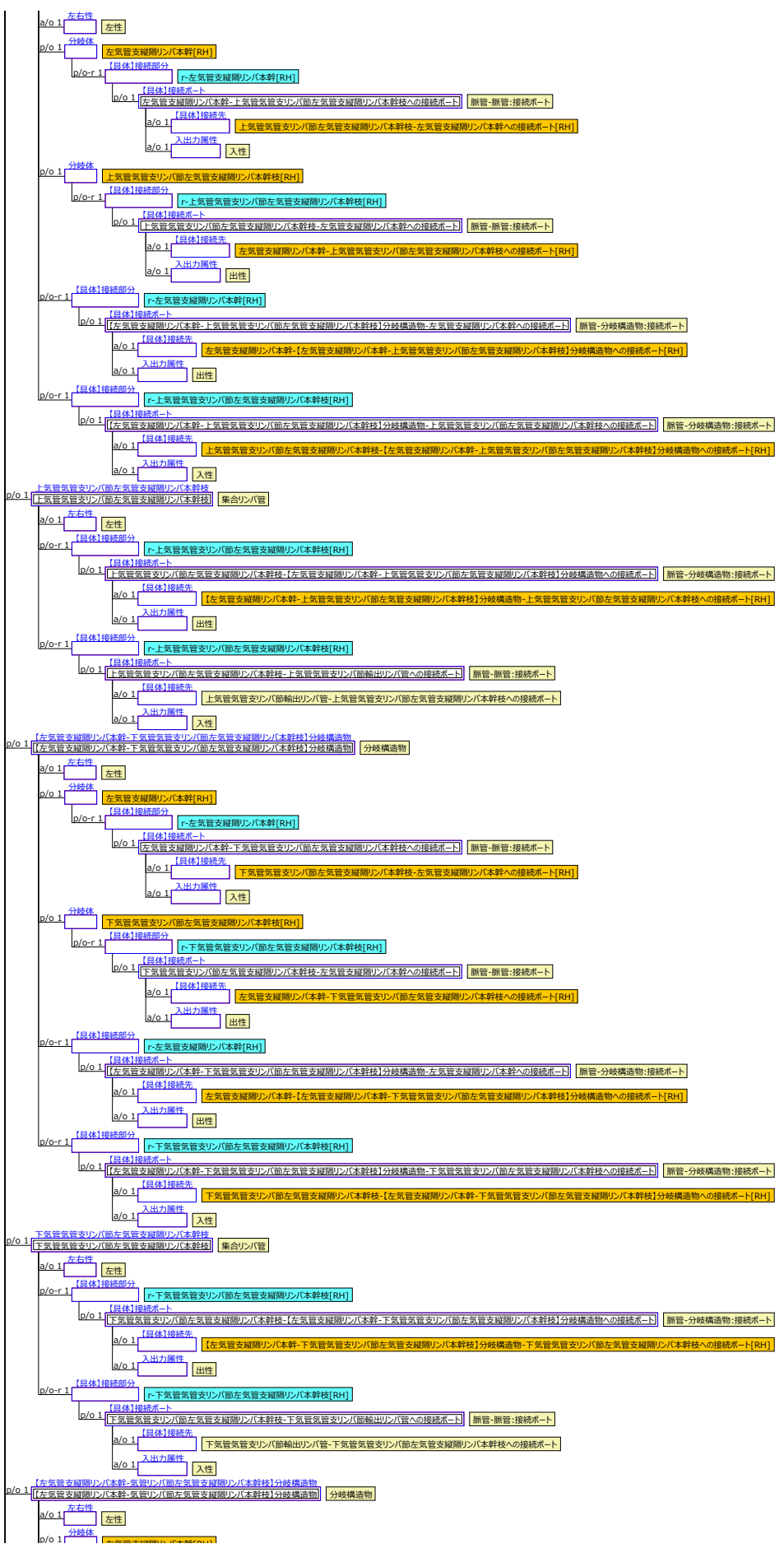




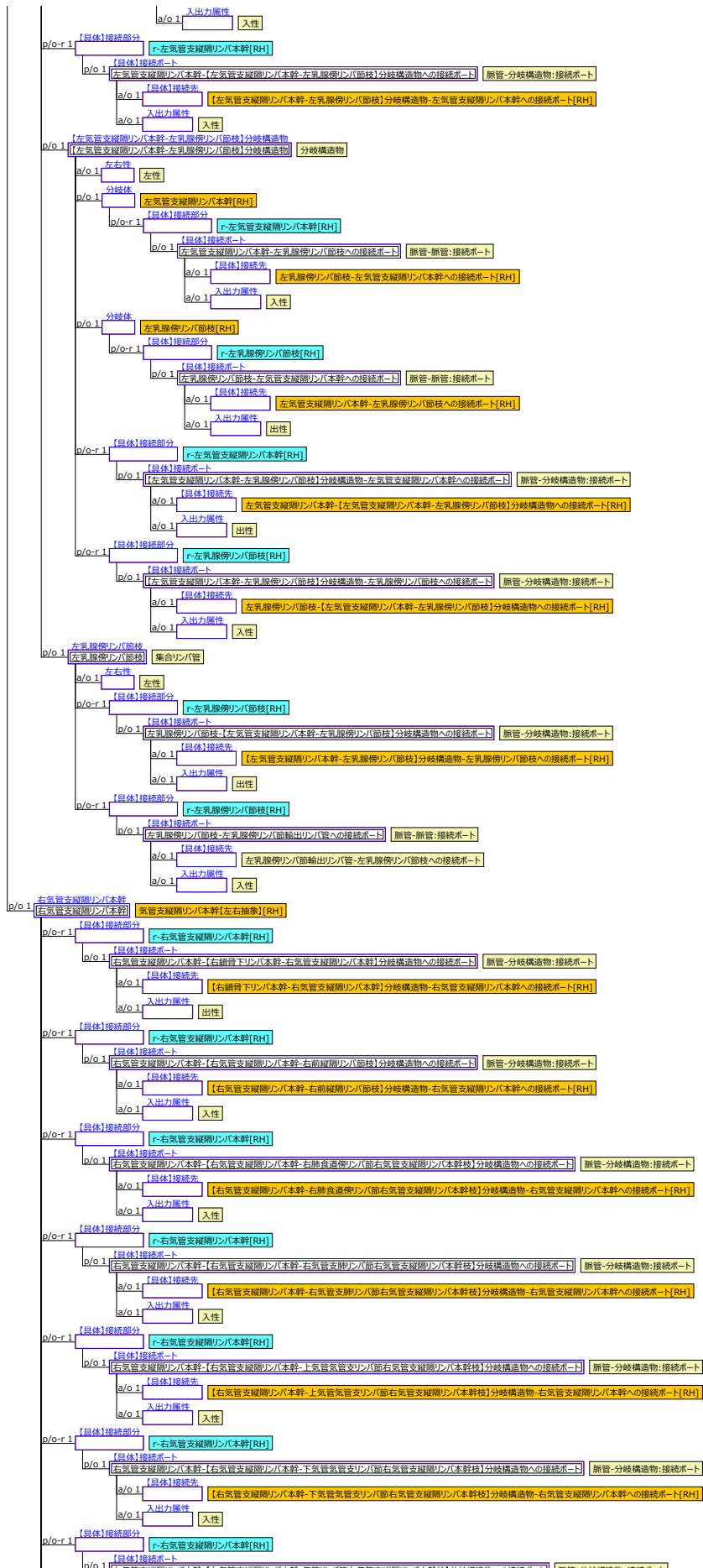




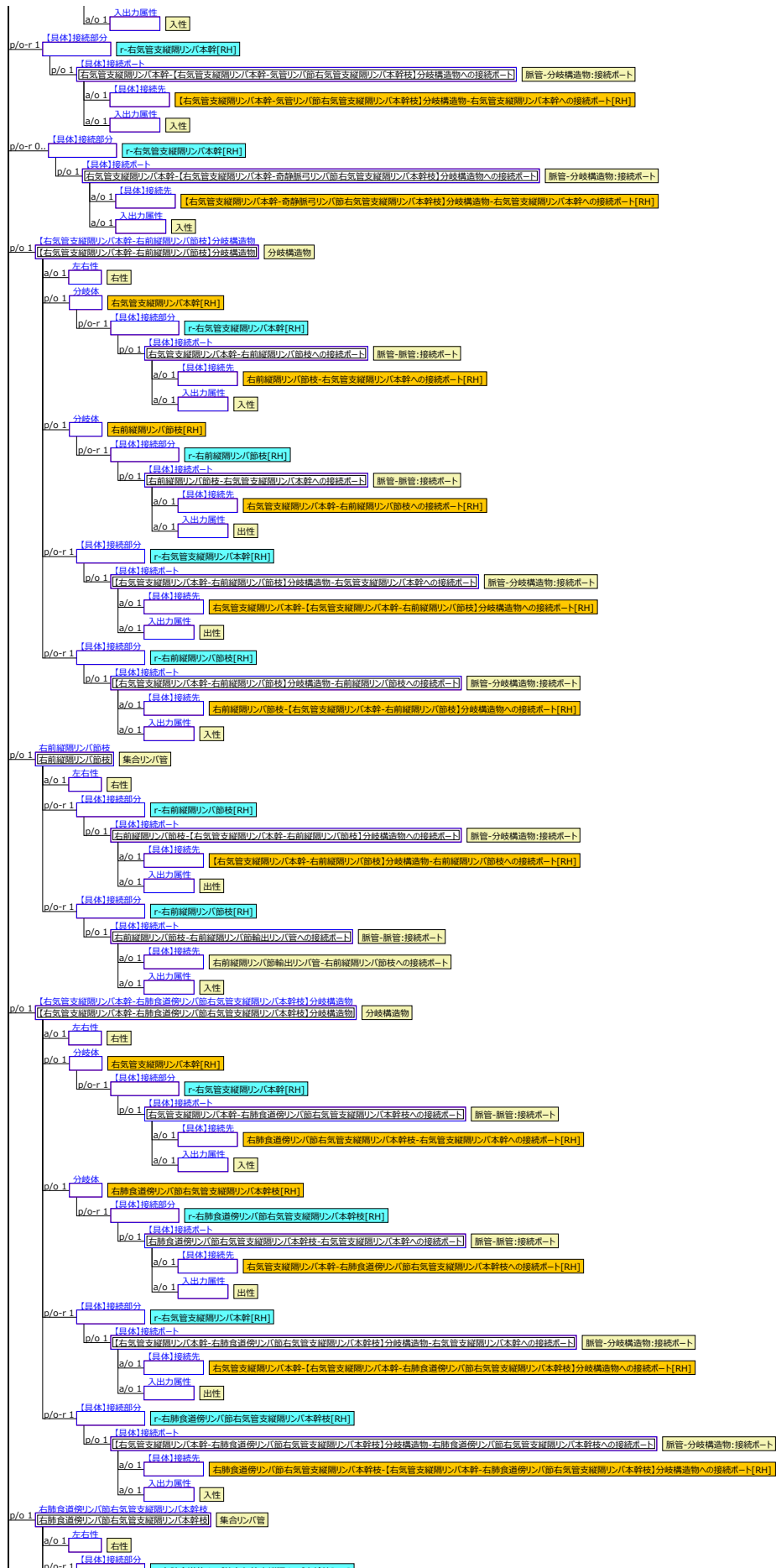


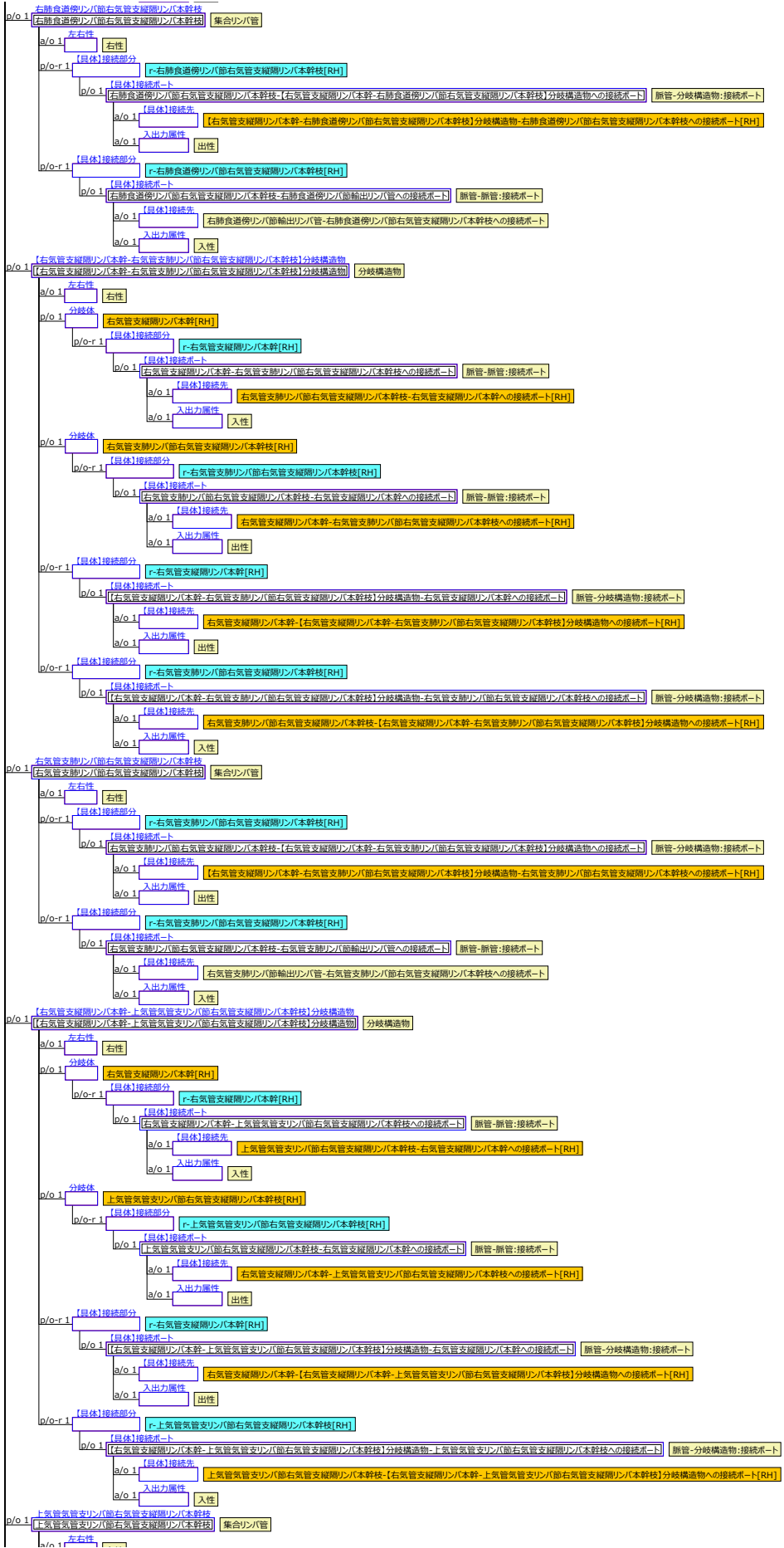


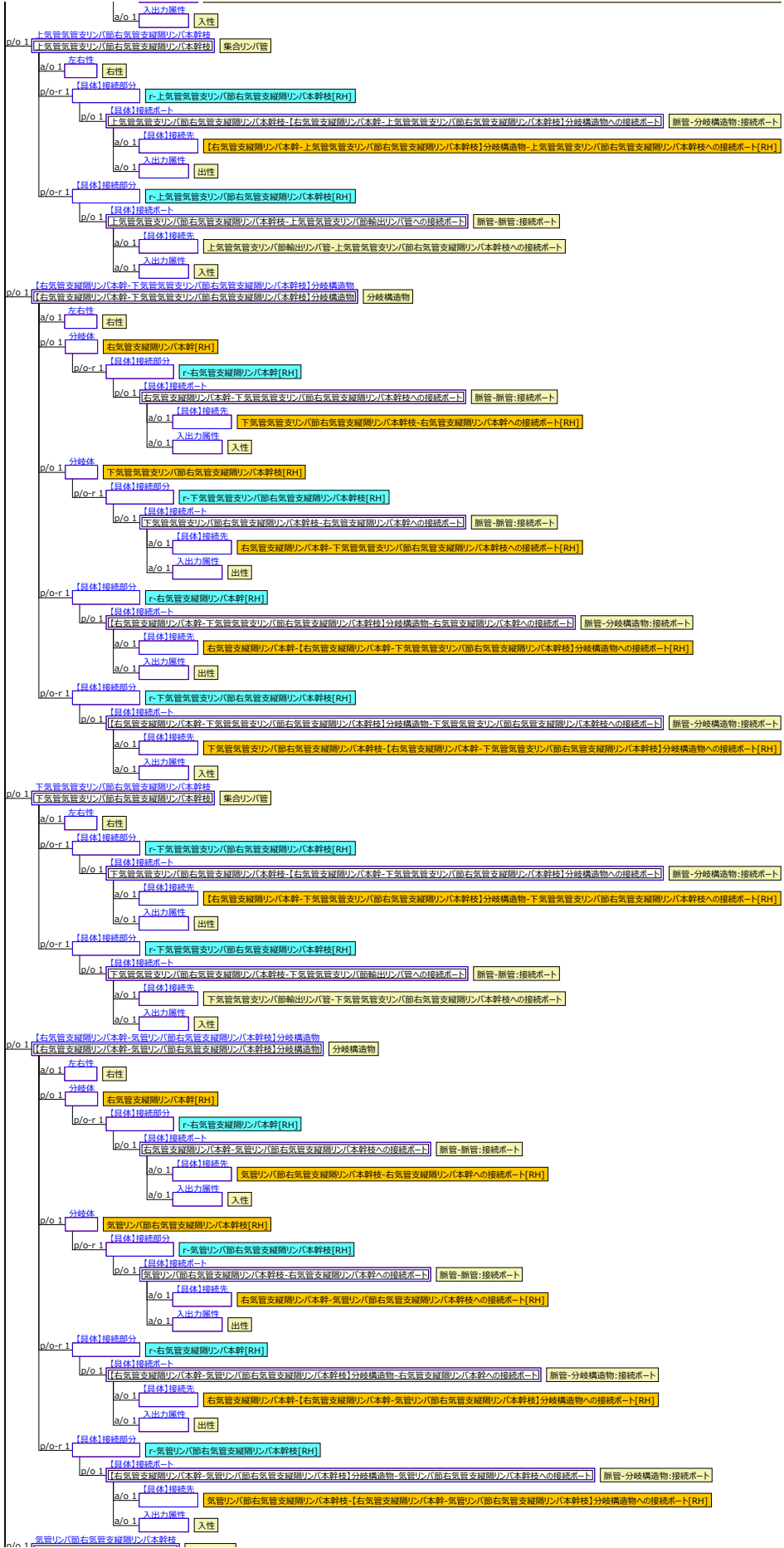


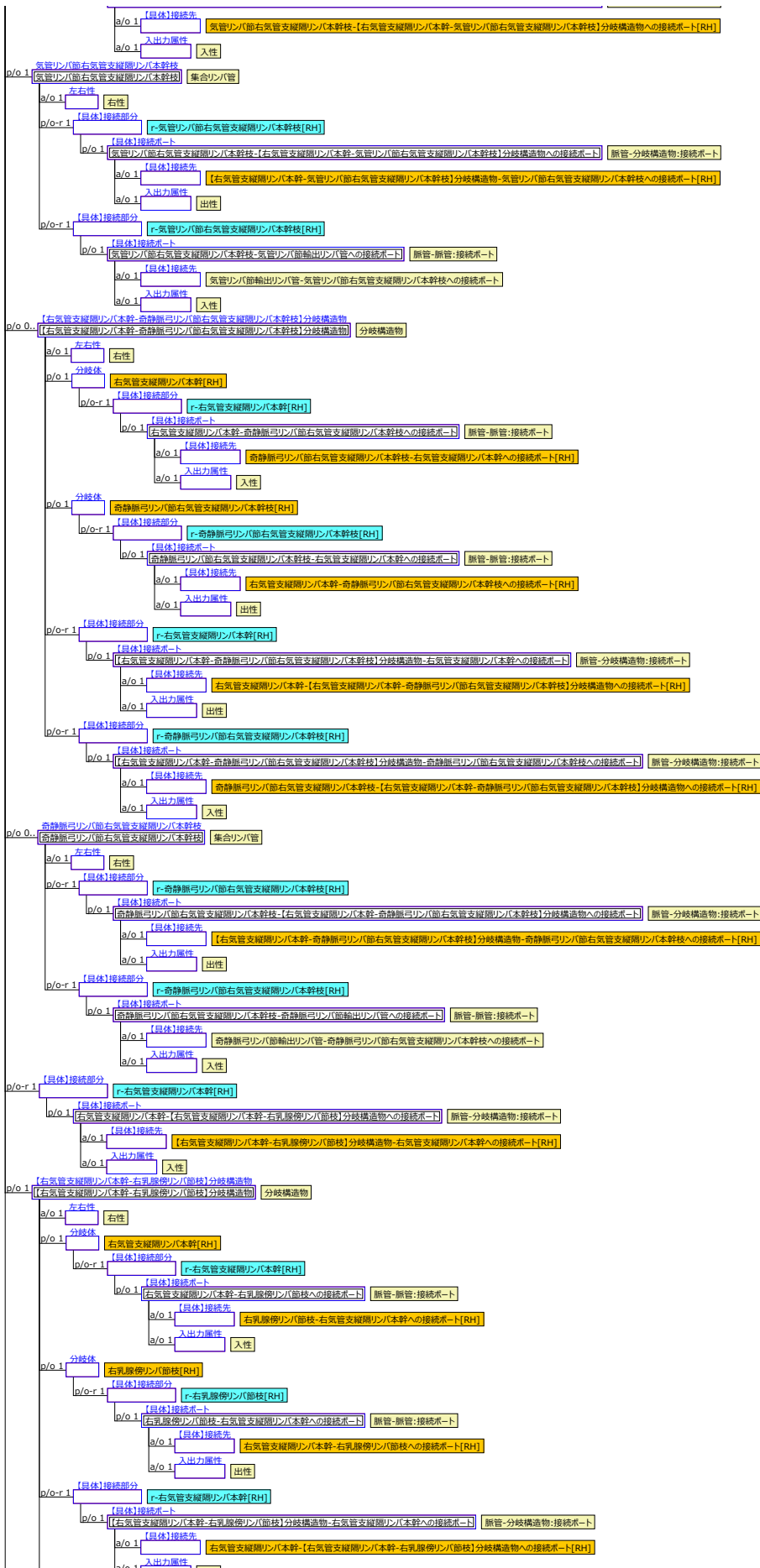


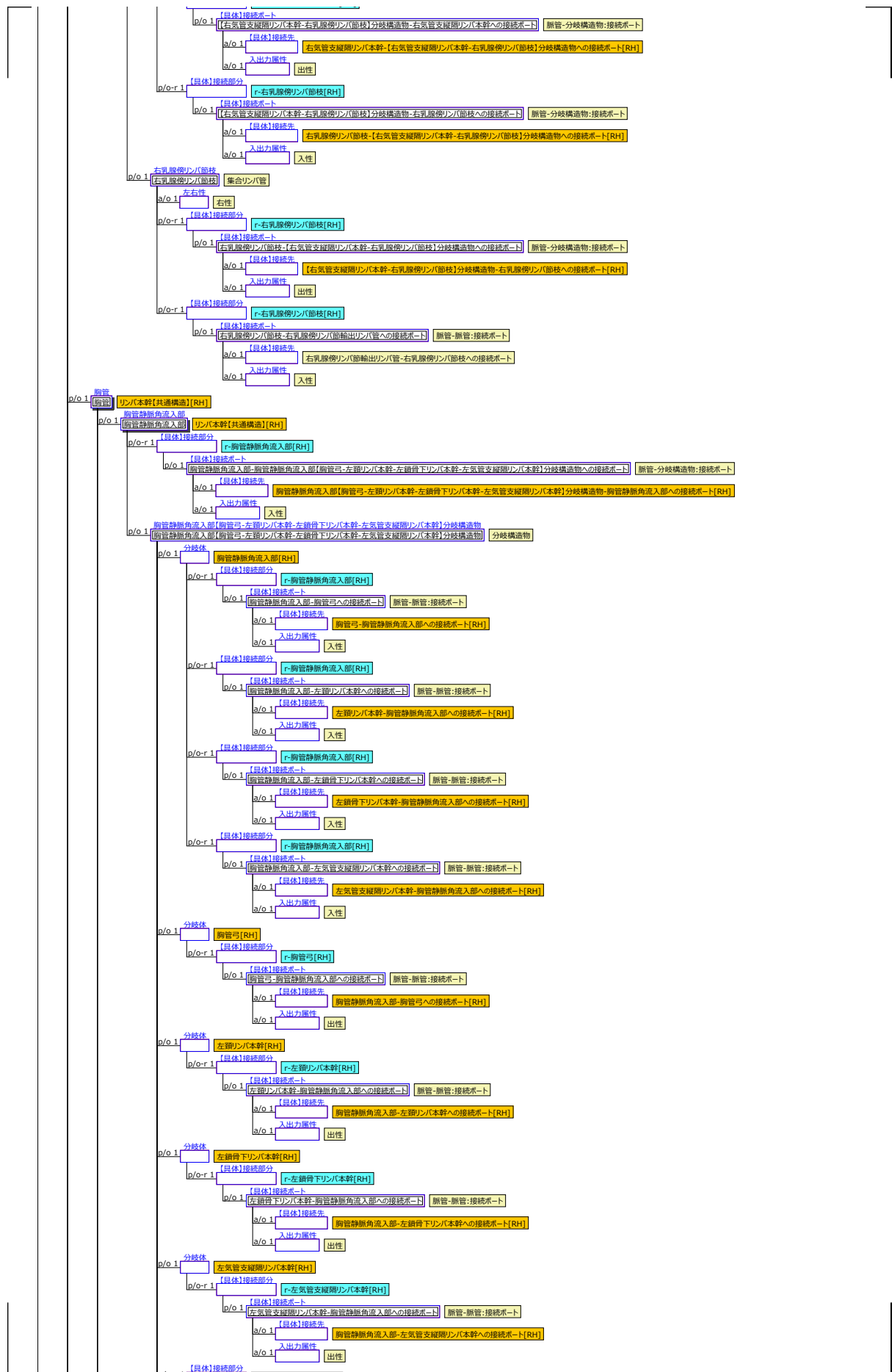


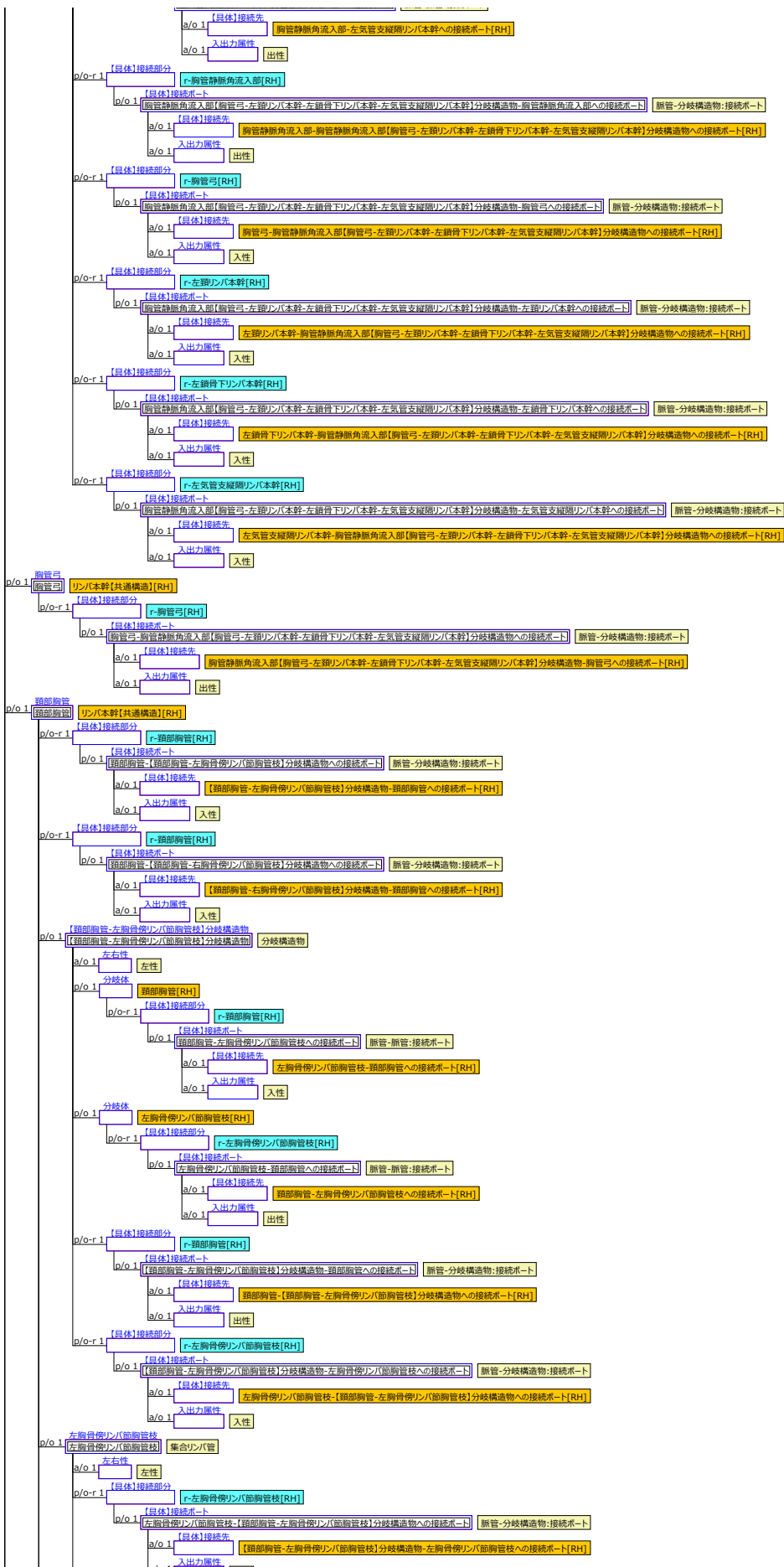


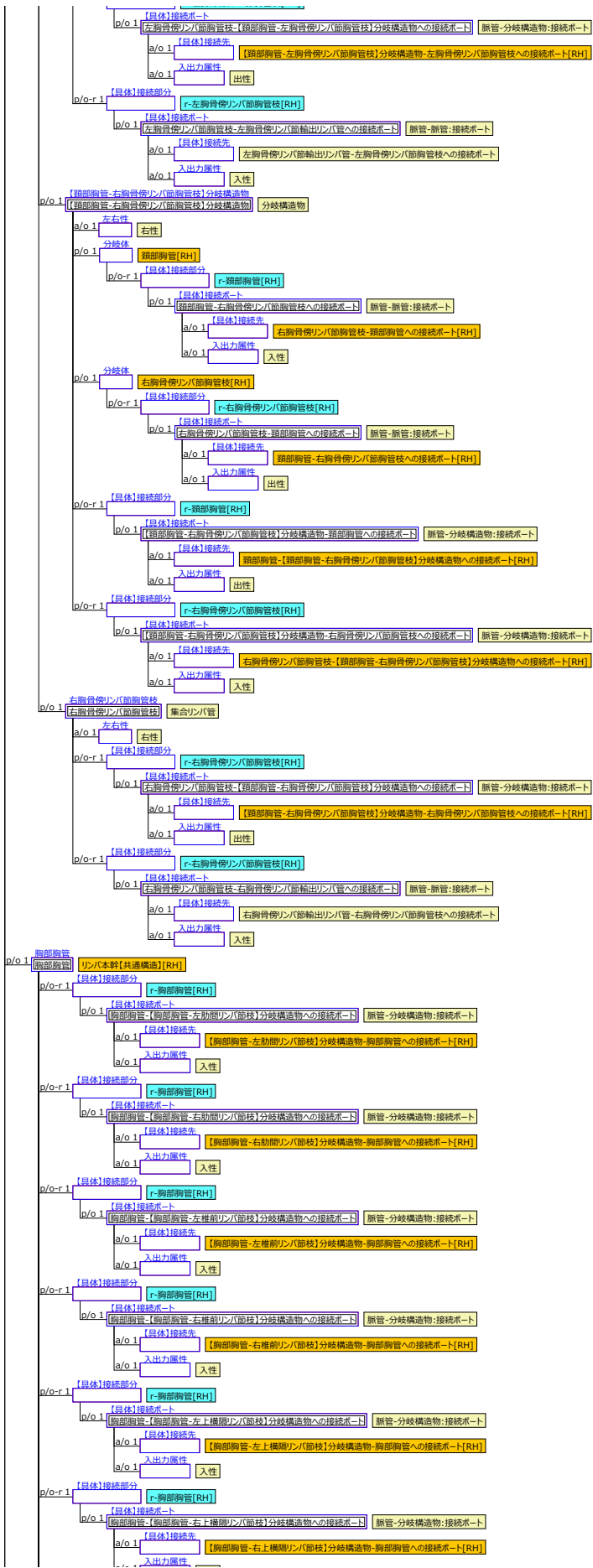


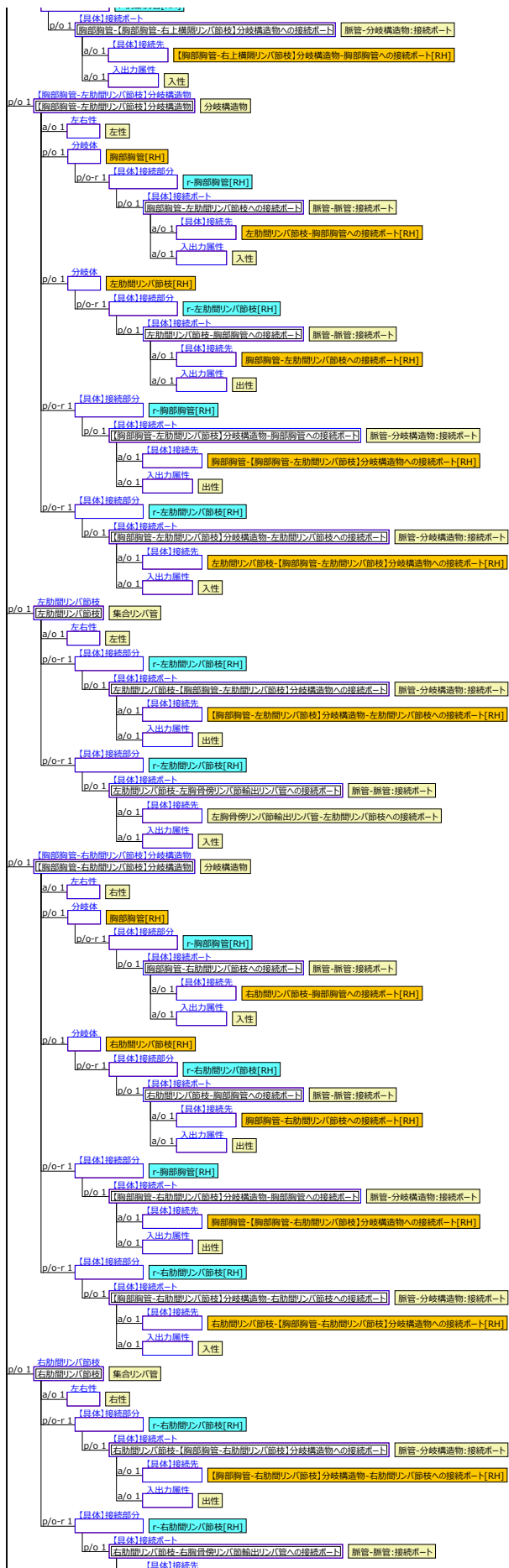




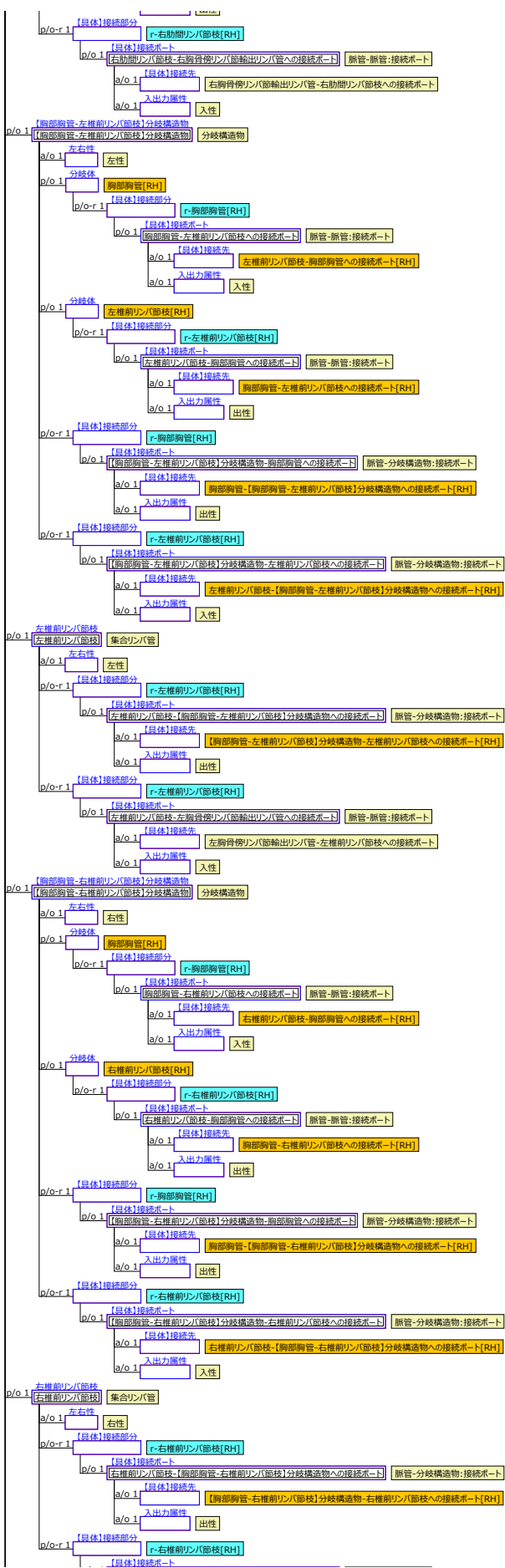


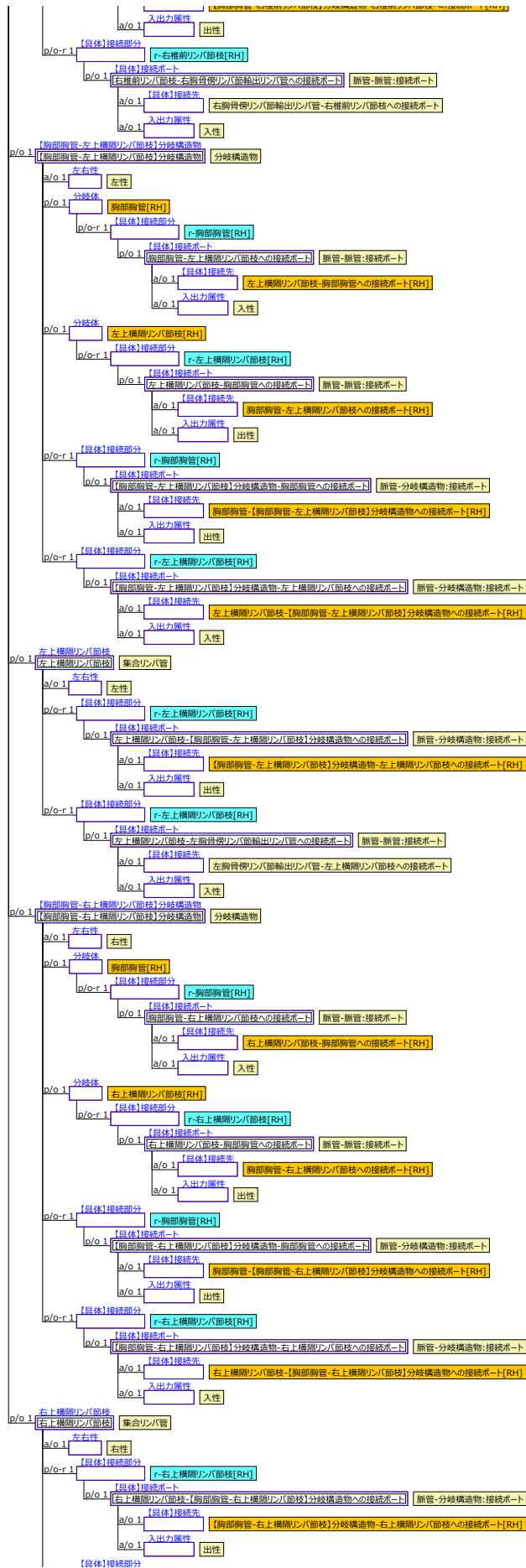


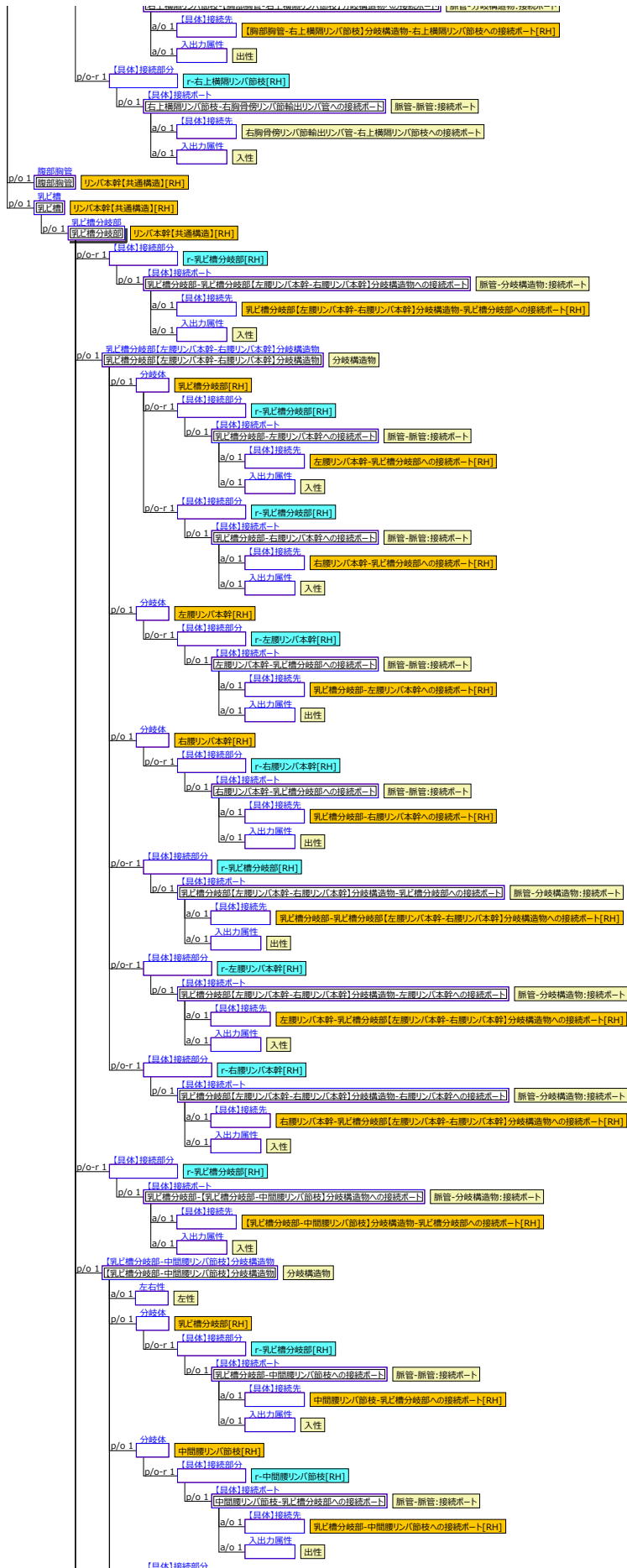


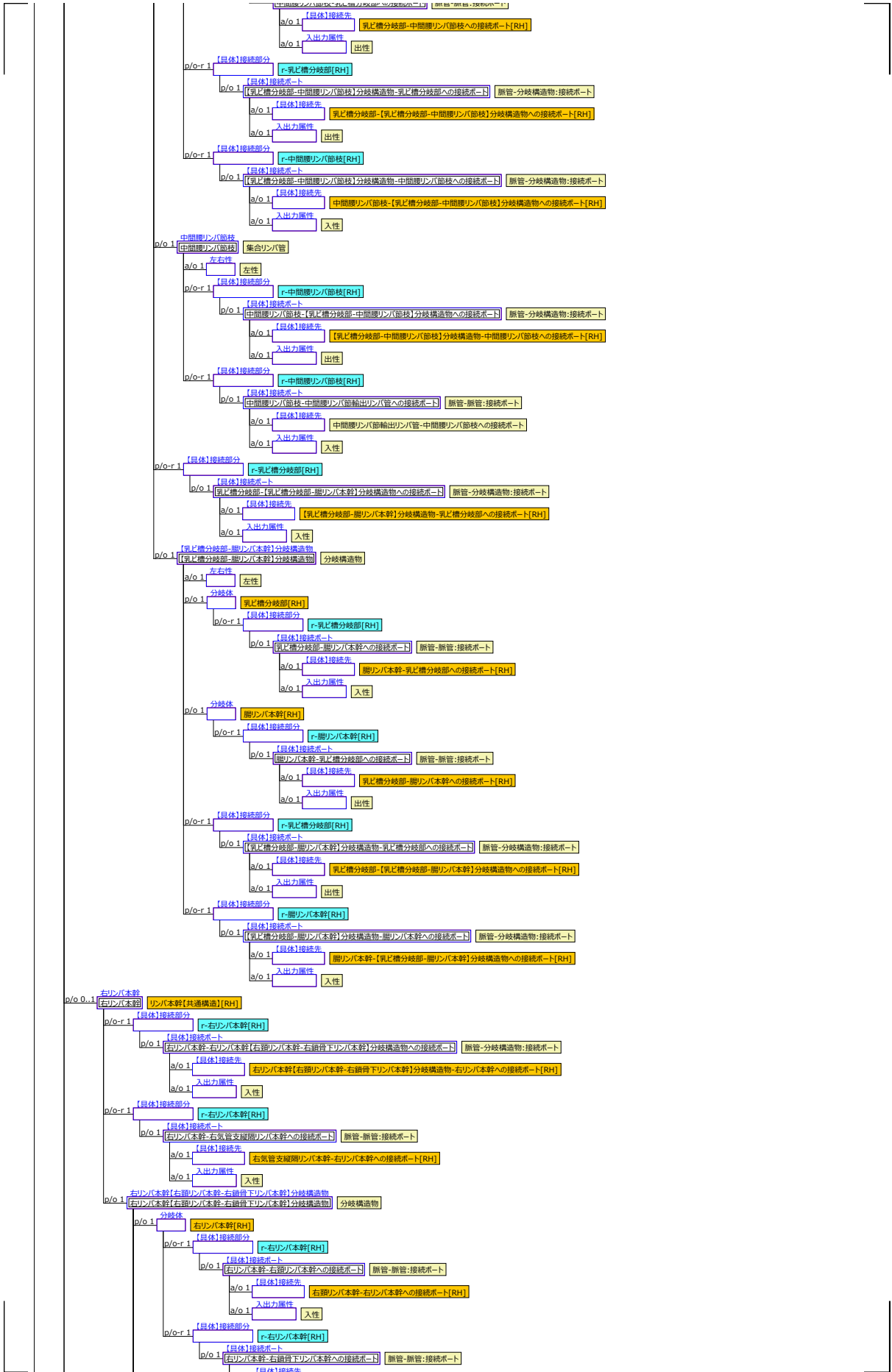


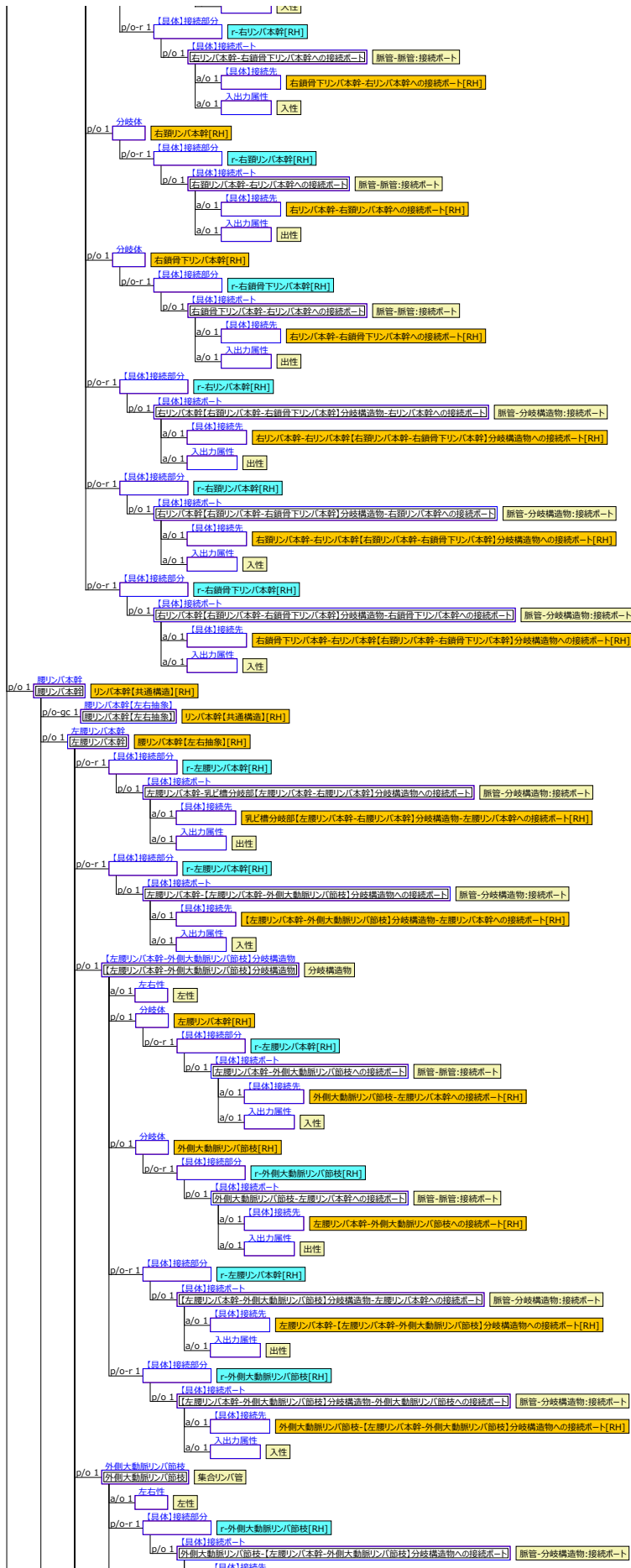


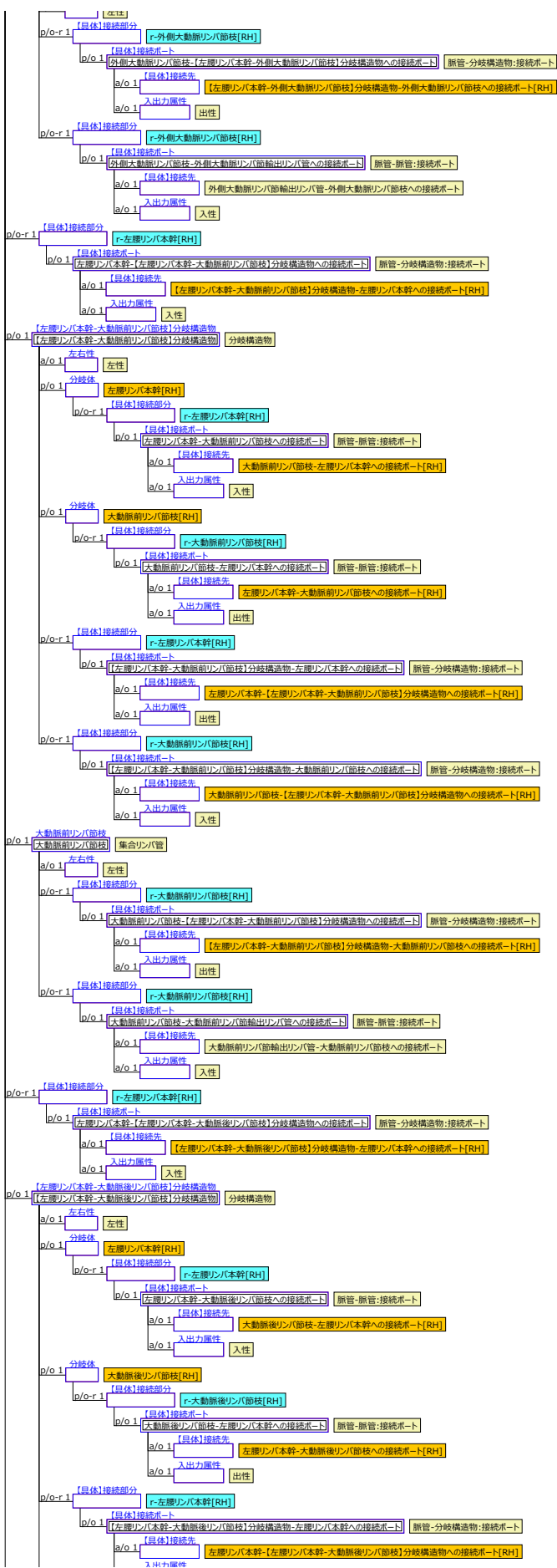


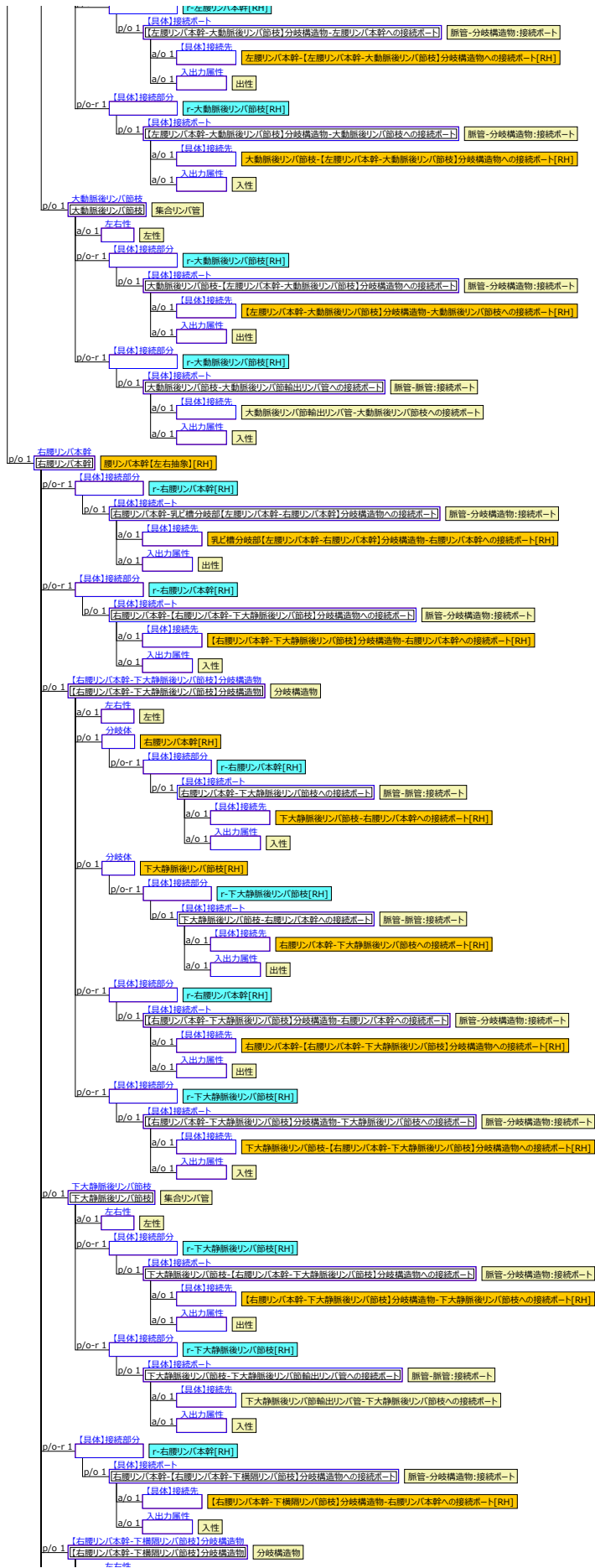












右腰リンパ本幹





